

**Zeitschrift:** Acta Tropica  
**Herausgeber:** Schweizerisches Tropeninstitut (Basel)  
**Band:** 32 (1975)  
**Heft:** 3

**Artikel:** Miscellanea : The histopathology of experimental disease produced in mice infected with "Trypanosoma vivax"  
**Autor:** Isoun, T.T.  
**DOI:** <https://doi.org/10.5169/seals-312091>

### **Nutzungsbedingungen**

Die ETH-Bibliothek ist die Anbieterin der digitalisierten Zeitschriften. Sie besitzt keine Urheberrechte an den Zeitschriften und ist nicht verantwortlich für deren Inhalte. Die Rechte liegen in der Regel bei den Herausgebern beziehungsweise den externen Rechteinhabern. [Siehe Rechtliche Hinweise.](#)

### **Conditions d'utilisation**

L'ETH Library est le fournisseur des revues numérisées. Elle ne détient aucun droit d'auteur sur les revues et n'est pas responsable de leur contenu. En règle générale, les droits sont détenus par les éditeurs ou les détenteurs de droits externes. [Voir Informations légales.](#)

### **Terms of use**

The ETH Library is the provider of the digitised journals. It does not own any copyrights to the journals and is not responsible for their content. The rights usually lie with the publishers or the external rights holders. [See Legal notice.](#)

**Download PDF:** 15.05.2025

**ETH-Bibliothek Zürich, E-Periodica, <https://www.e-periodica.ch>**

# The Histopathology of Experimental Disease Produced in Mice Infected with *Trypanosoma vivax*

T. T. ISOUN

## Abstract

An acute form of trypanosomiasis (course of disease 4 to 8 days) was produced in mice experimentally infected with a strain of *T. vivax*. The features of the disease were: a parasitemia which appeared to increase exponentially from  $23.8$  to  $243.6 \times 10^6$  trypanosomes per ml within the last 24 hours of the disease; anaemia was not severe in the disease in mice; the basic histological lesion was generalized fibrin thrombus formation in the blood vessels of the heart, lung, spleen and brain; trypanosome emboli were present in the brain, spleen and liver of infected mice.

The disease in mice could prove a useful model in studies of the pathogenesis of acute trypanosomiasis and also in studies in the mechanism of generalized intravascular coagulation.

## Introduction

*Trypanosoma vivax* infections of cattle and other ruminants constitute the major trypanosomiasis in West Africa. Studies of the biology of the organism have been hampered by the difficulty in establishing *T. vivax* in laboratory rodents or establishing it under *in vitro* conditions.

Several attempts have been made to establish *T. vivax* in rabbits (BLACKLOCK & YORK, 1913), rats (DESOWITZ & WATSON, 1952) and mice (UNSWORTH, 1953). TAYLOR (1968) studied the pathogenicity and infectivity in mice of rodent adapted *T. vivax*. However, there are no detailed reports in the literature of histopathological studies of the experimental disease produced in mice by *T. vivax*.

It is the purpose of these studies to characterize the experimental disease produced in mice infected with the Leeftlang strain of *T. vivax* as a possible model for the study of the pathogenesis of the acute form of the natural disease in ruminants.

## Materials and Method

The isolate of mice-adapted *T. vivax* (Zaria Y 58) was supplied by Professor P. Leeftlang, Department of Veterinary Parasitology and Entomology Ahmadu Bello University, Zaria Nigeria. The isolate originated from a natural infection in a N'dama cow and was successfully adapted to mice. It had undergone 4 passages in mice, two passages (6th) in cattle followed by another 131 (7th–137th) passages in mice and one more passage 138th in bovine before it was then deep frozen at  $-70^{\circ}\text{C}$  as a stablate. Finally it was passaged (139th) to mice for the current experiments.

Thirty mice (Inbred Albino Swiss) were used in these experiments; 25 were experimentally infected (5 mice in each in 5 consecutive passages) with this strain

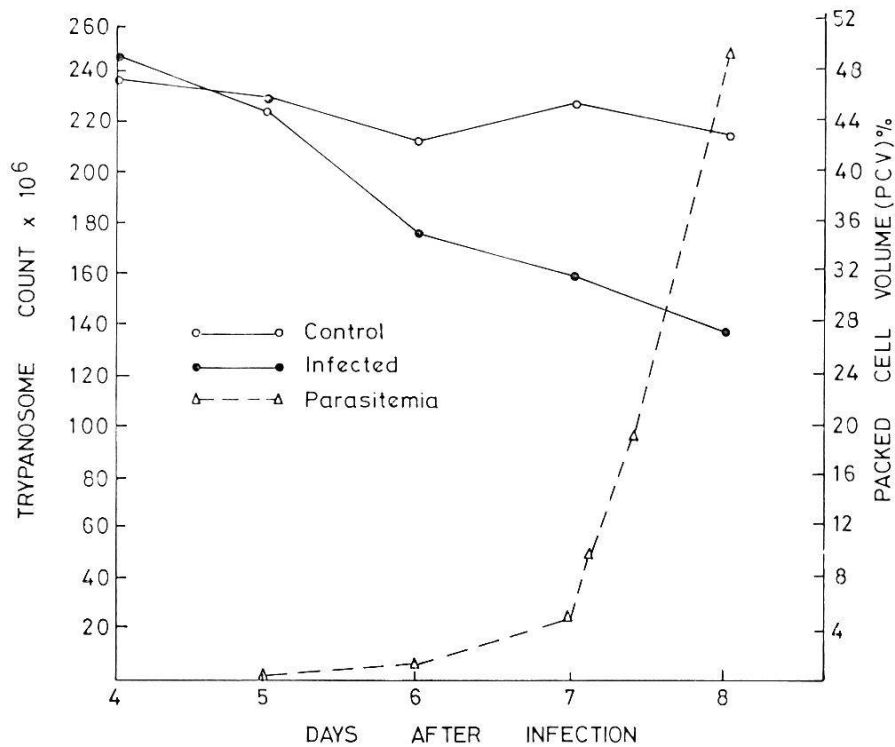


Fig. 1. Parasitemia and packed cell volume (PCV) of *T. vivax* infected and control mice.

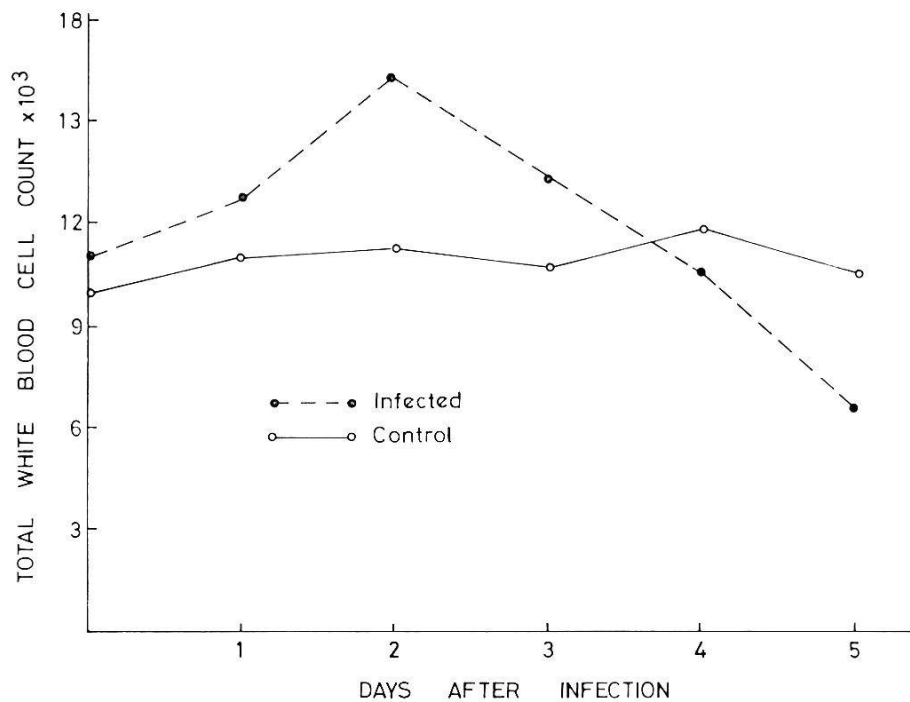


Fig. 2. Total white blood cell count (WBC) of *T. vivax* infected and control mice.

of *T. vivax* (each mice was inoculated with  $2 \times 10^6$  trypanosomes intraperitoneally). Five mice served as non infected controls.

Packed cell volume and total white blood cell count were determined by the method of BENJAMIN (1964). Parasitemia was determined once daily but during

Table 1. Differential count (percent) of peripheral blood leucocytes of mice experimentally infected with *T. vivax*

Leucocytes		Pre-Infection	1d PI	2d PI	3d PI	4d PI
Neutrophils	Immature	4	3	6	3	3
	Mature	14	5	16	26	38
Lymphocytes		79	88	63	66	45
Monocytes		1	4	15	5	14
Eosinophils		—	—	—	—	—
Basophils		2	—	—	1	—

Each value is a mean of 5 animals. PI = Post-Infection, d = day.

the terminal stages of the disease twice daily by dilution of blood in a fixative – staining solution (0.5% toluidine blue, 1% sodium citrate, 10% formalin in distilled water) and counting in a haemocytometer. For purpose of studying the tissue changes in the course of the disease, one mice in each group was killed on each day of parasitemia; one animal was allowed to die of the experimental disease in every group. Post-mortem examination was performed on all animals – those that were killed and those dying from the experimental disease. Smears of organs of the mice were fixed in alcohol and stained with Giemsa.

Tissues taken at necropsy were fixed in formalin, Bouin and Zenker; sectioned at 6 microns and stained with haematoxylin and eosin, Martius Scarlet Blue (MSB) and Prussian Blue.

## Results

The packed cell volume (PCV) and the daily parasitemia of the infected mice are presented in Fig. 1. In the course of the patent infection (range 4 to 8 days) the PCV decreased from a normal of 48% to 27%. The highest parasitemia recorded in the course of the disease was  $243.6 \times 10^6$  trypanosomes per ml; the parasitemia in the terminal stages of the disease appeared to increase exponentially from  $23.8 \times 10^6$  to  $243.6 \times 10^6$  trypanosomes per ml within 24 hours.

The total white blood cell count (WBC) and the differential peripheral leucocyte count in *T. vivax* infected mice are presented in Fig. 2 and Table 1.

Apart from an initial increase of total WBC count 2 days after infection, the WBC count in infected mice decreased to  $5 \times 10^3$  cells per  $\text{mm}^3$  (normal  $10 \times 10^3$  cells per  $\text{mm}^3$ ). Peripheral lymphocytes decreased but monocytes and neutrophils increased in the terminal stages of the disease.

On the second day of parasitemia, lesions histologically were minimal: lymphoid hyperplasia characterized the splenic corpuscles. Network of fibrin (not severe enough to form a thrombus) and nuclei of trypanosomes were noticeable in the medium size blood vessels of the liver, and lung on the third day of parasitemia. The additional lesion in the spleen on the third day of parasitemia was depletion of mature lymphocytes and hyperplasia of reticular cells in the red pulp.

On the fourth day of parasitemia, the strands of fibrin in medium-sized blood vessels of the liver, lung, spleen have increased to constitute fibrin thrombosis.

The lesions on the fifth day of parasitemia constitute essentially those of the terminal stages of the disease. The red pulp of the spleen of mice was characterized by hyperaemia with haemosiderosis (Prussian blue stain); some of the blood vessels contained accumulation of trypanosome nuclei (emboli), others showed proteinaceous pink staining hyaline thrombi. Severe depletion of mature lymphocytes was noticeable in the red pulp. The reticular and megakaryotic cells had undergone hyperplasia. Although the periphery of the germinal centres were depleted of mature lymphocytes, the rest of the germinal centre was adequately populated with lymphocytes but showed reticular cells with abundant pink-staining cytoplasm.

The lymph nodes were characterized by lack of differentiation of germinal centres and by lymphoid hyperplasia. The lesions in the liver of mice were characterized by accumulation of lymphocytes in the portal triads; diffuse fatty metamorphosis, and in blood vessels (MSB Stain) by a network of fibrin thrombi (not necessarily coexisting with trypanosome emboli), sludging of blood and some blood vessels containing trypanosome nuclear debris (embolus).

The tissue changes in the lungs, heart and brain were primarily vascular; some blood vessels contained a network of fibrin thrombi (Figs. 3–4) and others contained trypanosome nuclear debris (Fig. 5).

The pattern of parasitemia, PCV, total and differential white blood cell counts and the lesions described were reproduced in all the five passages of *T. vivax* in mice.

### Discussion

The experimental disease in mice infected with *T. vivax* is of the acute type: its course (patent infection) ranged from 4 to 8 days. Although anaemia was present, it was not as severe and prolonged as the natural disease in ruminants. The pattern of the parasitemia in the mice was striking, particularly what appears as exponential growth (about 3 cell cycles) in the terminal 24 hours of the disease. The exponential growth of this isolate of *T. vivax* may be useful in studies of growth kinetics and *in vivo* metabolism of this organism.

The total and differential white cell count and indeed the histological lesions produced in the spleen and lymph nodes of *T. vivax* infected mice indicate the interaction of the infection and the lymphoreticular system. The lymphoreticular system is one of the target organs in terms of response in animal trypanosomiasis. The experimental disease may be useful in studies of the pathogenesis of the lymphoreticular response and immunity in trypanosomiasis.

One of the primary lesions in the experimental disease is disseminated intravascular fibrin thrombosis and trypanosome embolism (the two lesions do not necessarily co-exist) involving the brain, heart, spleen, lung and liver. Similar lesions are present in the acute form of the disease in cattle (ISOUN & ESURUOSO, 1972) and goats (ISOUN & ANOSA, 1974).

It is much less expensive to perform animal experiments in mice and the experimental disease in mice would therefore serve as a useful model for the study of the pathogenesis of intravascular coagulation and other vascular dynamic changes caused by *T. vivax* and *T. simiae* (ISOUN, 1968, and VAN DIJK, ZWART & LEEFLANG, 1973).

### Acknowledgement

I wish to thank the Rockefeller Foundation and the Senate of the University of Ibadan for financial support. The technical help of Messrs A. O. Udoh, M. A. Arasi and Mrs. S. Enenebeaku is appreciated. My thanks are due to Professor P. Leeflang for the strain of *T. vivax* and Peter C. Amajuoyi for typing the paper.



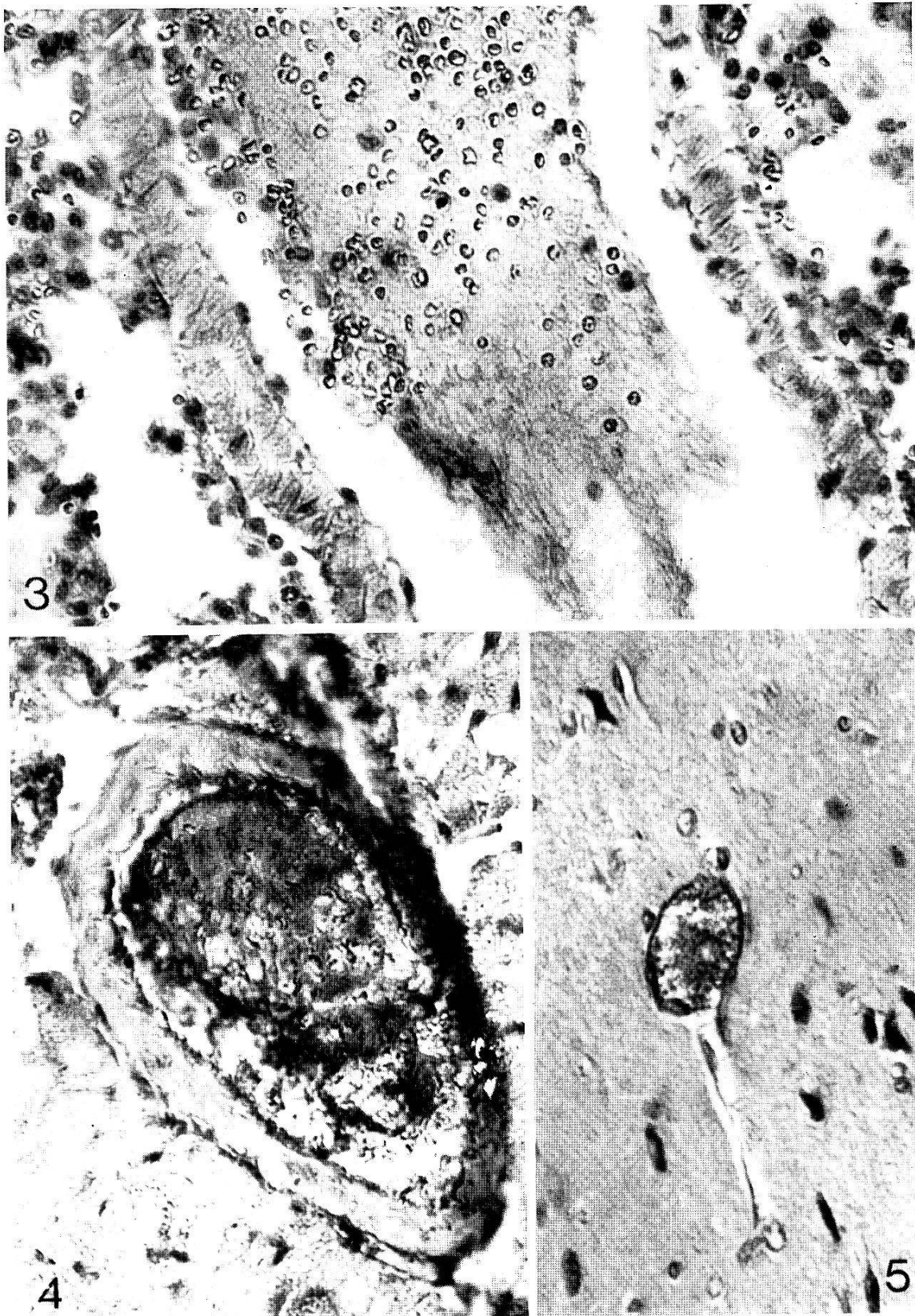


Fig. 3. Section of lung of *T. vivax* infected mice. Fibrin thrombus MSB  $\times 250$ .

Fig. 4. Section of heart of *T. vivax* infected mice. Intravascular (fibrin) coagulation MSB  $\times 250$ .

Fig. 5. Section of brain of *T. vivax* infected mice. Note trypanosome embolus MSB  $\times 100$ .

## References

- BLACKLOCK, B. & YORKS, W. (1913). *Trypanosoma vivax* in rabbits. – Ann. trop. Med. Parasit. 7, 563–568.
- BENJAMIN, M. M. (1964). Outline of Veterinary Clinical Pathology. – Iowa State University Press. Ames.
- DESOWITZ, R. S. & WATSON, H. J. C. (1952). Studies on *Trypanosoma vivax*: Observations on the maintenance of a strain in white rats. – Ann. trop. Med. Parasit. 46, 92–100.
- ISOUN, T. T. (1968). The pathology of *Trypanosoma simiae* infection in pigs. – Ann. trop. Med. Parasit. 62, 188–192.
- ISOUN, T. T. & ESURUOSO, G. O. (1972). Pathology of natural infection of *Trypanosoma vivax* in cattle. – Nig. vet. J. 1, 42–45.
- ISOUN, T. T. & ANOSA, V. O. (1974). Lesions in the reproductive organs of sheep and goats experimentally infected with *Trypanosoma vivax*. – Z. Tropenmed. Parasit. 25, 469–476.
- TAYLOR, A. E. R. (1968). Studies on the rodent strain of *Trypanosoma vivax*. – Ann. trop. Med. Parasit. 62, 375–381.
- VAN DIJK, J. E., ZWART, D. & LEEFLANG, P. (1973). A contribution to the pathology of *Trypanosoma simiae* infection in pigs. – Zbl. Vet.-Med. 20, 374–391.
- UNSWORTH, K. (1953). Studies on *Trypanosoma vivax*. The maintenance of a strain in mice with observations on the effects of splenectomy. – Ann. trop. Med. Parasit. 47, 232–239.