

**Zeitschrift:** Acta Tropica  
**Herausgeber:** Schweizerisches Tropeninstitut (Basel)  
**Band:** 40 (1983)  
**Heft:** 2

**Artikel:** Serum ferritin in Nigerian patients with amoebic liver abscess and other tropical infections with liver involvement  
**Autor:** Bolarin, D.M.  
**DOI:** <https://doi.org/10.5169/seals-313128>

### **Nutzungsbedingungen**

Die ETH-Bibliothek ist die Anbieterin der digitalisierten Zeitschriften. Sie besitzt keine Urheberrechte an den Zeitschriften und ist nicht verantwortlich für deren Inhalte. Die Rechte liegen in der Regel bei den Herausgebern beziehungsweise den externen Rechteinhabern. [Siehe Rechtliche Hinweise.](#)

### **Conditions d'utilisation**

L'ETH Library est le fournisseur des revues numérisées. Elle ne détient aucun droit d'auteur sur les revues et n'est pas responsable de leur contenu. En règle générale, les droits sont détenus par les éditeurs ou les détenteurs de droits externes. [Voir Informations légales.](#)

### **Terms of use**

The ETH Library is the provider of the digitised journals. It does not own any copyrights to the journals and is not responsible for their content. The rights usually lie with the publishers or the external rights holders. [See Legal notice.](#)

**Download PDF:** 15.05.2025

**ETH-Bibliothek Zürich, E-Periodica, <https://www.e-periodica.ch>**

Department of Pathology, University of Ife, Ile-Ife, Nigeria

## **Serum ferritin in Nigerian patients with amoebic liver abscess and other tropical infections with liver involvement**

D. M. BOLARIN

### **Summary**

Serum ferritin was measured by immunoradiometric assay in 46 Nigerian patients with amoebic liver abscess and other tropical infections involving the liver, and the values were compared with those in 23 control subjects. Serum ferritin was markedly elevated in 100% of the patients with amoebic liver abscess, acute viral hepatitis and liver tuberculosis. Elevated values were observed in about 77% of patients with cirrhosis, 80% of malaria patients, and only about 30% of patients with early infection of schistosomiasis mansoni. The results support previous data indicating that significant changes in serum ferritin occur in acute and chronic liver disease. Assay of serum ferritin may be a useful complementary liver function test for the diagnosis and monitoring the treatment provided in amoebic liver abscess.

**Key words:** amoebic liver abscess; serum ferritin; tropical liver infections.

### **Introduction**

Amoebic liver abscess is the most common complication of amoebic colitis. It is essentially a disease of the tropics and subtropics (Sherlock, 1981). The diagnosis of amoebic liver abscess is often difficult even in areas where it is common (Dorrough, 1967).

Ferritin, a primarily intracellular iron storage protein of the body is found in all tissues, but in particularly high concentrations in the liver, spleen and bone marrow (Zuyderhoudt et al., 1978; Nelson et al., 1978; Jacobs and Worwood, 1975). The introduction of a sensitive immunoradiometric assay for ferritin (Addison et al., 1972) has greatly enhanced our ability to measure small

---

Correspondence: Dr. Debayo M. Bolarin, Searle Research and Development, Division of G.D. Searle & Co., 4901 Searle Parkway, Skokie, Illinois 60077, USA

Table 1

Group	n	Sex		Age*	Serum ferritin* ( $\mu\text{g/l}$ )	p**
		♂	♀			
Controls . . . . .	23	12	11	32 $\pm$ 14	105.78 $\pm$ 73.90	—
Amoebic liver abscess . . . . .	9	8	1	39 $\pm$ 9	5755.60 $\pm$ 4563	<0.00001
Acute viral hepatitis . . . . .	10	4	6	29 $\pm$ 14	1159.00 $\pm$ 659.00	<0.00001
Cirrhosis . . . . .	9	6	3	51 $\pm$ 17	997.22 $\pm$ 665.18	<0.00001
Liver tuberculosis . . . . .	3	1	2	15 $\pm$ 4	660.00 $\pm$ 34.60	<0.00001
Malaria . . . . .	5	3	2	25 $\pm$ 20	242.00 $\pm$ 109.00	<0.003
Early infection of schisto- somiasis mansoni . . . . .	10	7	3	18 $\pm$ 4	218.00 $\pm$ 141.00	<0.007

\* Mean  $\pm$  SD

\*\* Statistical significance of difference in serum ferritin when compared with the control (Student's t test)

amounts of ferritin in normal serum and to determine changes in the serum ferritin concentrations in patients with a variety of pathological conditions. Serum ferritin level closely reflects the size of the iron stores and might provide a clinically useful index of storage iron (Walters et al., 1973; Lipschitz et al., 1974).

High serum ferritin concentration without iron overload has been found in chronic inflammation (Zucker et al., 1974), in acute and chronic liver disease (Prieto et al., 1975) and in a variety of human malignancies including primary hepatocellular carcinoma (Jones et al., 1973; Mori et al., 1975; Grail et al., 1982; Patel et al., 1980; Tomoda et al., 1982). No attempts to measure serum ferritin in amoebic liver abscess or in schistosomiasis mansoni (a parasitic infection which involves the liver) have been reported so far.

This preliminary communication reports on our initial experience in the clinical application of immunoradiometric assay for the measurement of serum ferritin in certain common tropical diseases including amoebic liver abscess and early infection of schistosomiasis mansoni.

## Materials and Methods

### *Patients and controls*

Sera were obtained from 23 apparently healthy Nigerian control subjects, 12 males and 11 females, mean age 32 years (15–60); 46 patients with various liver diseases and parasitic infections, 9 with amoebic liver abscess, 8 males and 1 female, mean age 39 years (32–60); 10 patients with acute viral hepatitis, 4 males and 6 females, mean age 29 years (12–62); 9 patients with cirrhosis, 6 males and 3 females, mean age 51 years (36–89); 3 patients with liver tuberculosis, 1 male and 2 females, mean age 15 years (10–18); 5 patients with malaria, 3 males and 2 females, mean age 25 years (13–

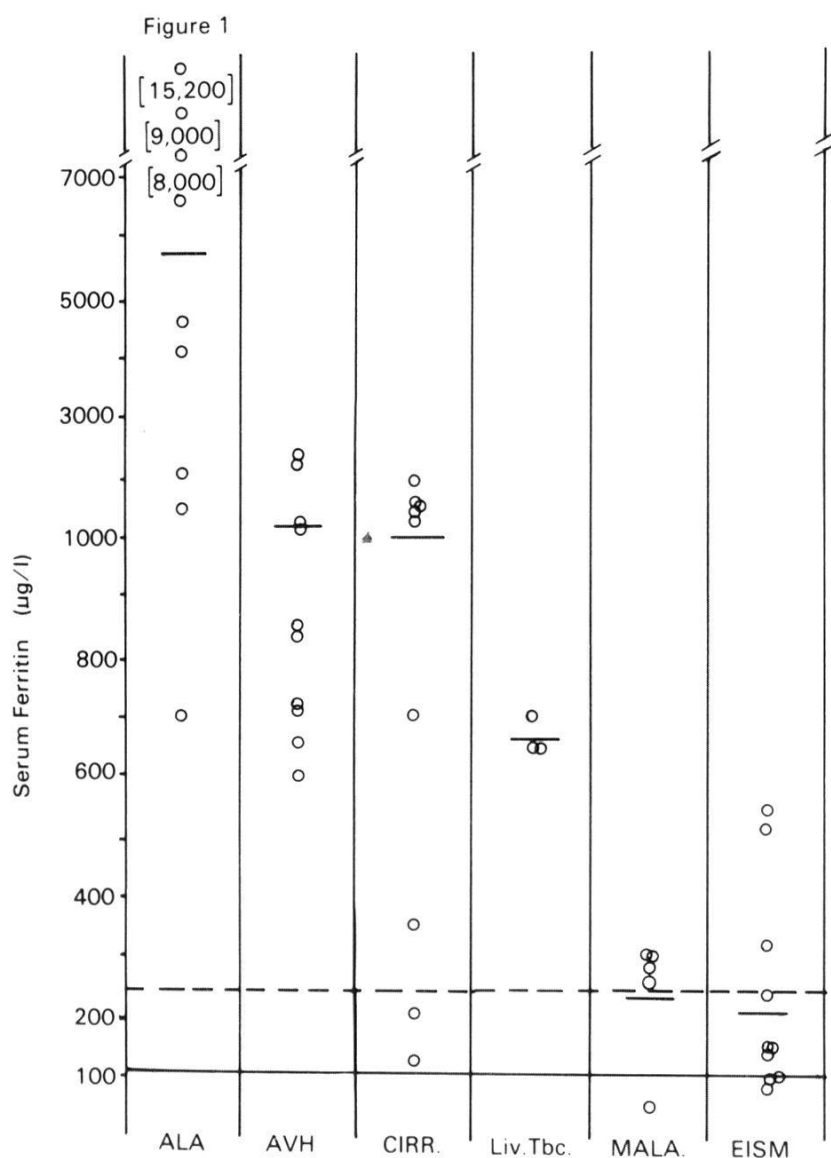


Fig. 1. Serum ferritin in patients with amoebic liver abscess (ALA), acute viral hepatitis (AVH), cirrhosis (CIRR), liver tuberculosis (Liv.Tbc.), malaria (MALA.) and early infection of schistosomiasis mansoni (EISM). The horizontal dashed line indicates the limit of the mean + 2 SD of the controls, the solid line the mean of the controls, and the short solid lines the means for the various patient groups.

60) and 10 patients with early infection of schistosomiasis mansoni, 7 males and 3 females, mean age 18 years (6–19). Most of the patients had been admitted to the various wards of the University of Ife Teaching Hospitals, while others were seen at the Outpatient Clinics of the same hospitals. The diagnosis had been confirmed in some of the cases by histological examination of hepatic specimen obtained either by percutaneous needle biopsy, by laparotomy or at autopsy. The diagnosis of amoebic liver abscess was further confirmed by the results of a diagnostic needle aspiration of the abscess; this readily yielded a large amount of typical pus – the «anchovy or chocolate sauce». The malaria and the early infection of schistosomiasis mansoni group had their diagnoses confirmed by light microscopical demonstration of the malaria parasites in the blood film but the presence of characteristically oval shaped egg with lateral spine in faeces in the cases of schistosomiasis mansoni.

## Assays

Venous blood was drawn from each patient at the time of initial diagnosis. Serum was separated after allowing the blood sample to coagulate at room temperature and all the sera samples including controls were stored at  $-20^{\circ}\text{C}$  until assayed. Serum ferritin concentration was determined using an immunoradiometric assay kit (Nordiclab Ltd., Oulu, Finland). The assays were performed on three different dilutions of the patient's sample to avoid the risk of falsely low results (Green et al., 1977). Calculation of the results was conducted with the aid of a standard curve run in parallel with each series of analytical samples. The serum ferritin concentration of all samples are expressed as  $\mu\text{g/l}$ .

The statistical significances of the difference between two means were calculated by Student's *t* test.

## Results

The mean serum ferritin levels in apparently healthy Nigerian subjects and those with various liver diseases including schistosomiasis mansoni and malaria are given in Table 1. In healthy Nigerian subjects, serum ferritin levels were comparable to those reported in the literature (Prieto et al., 1975; Cook et al., 1974). The mean serum ferritin concentration was significantly elevated in amoebic liver abscess, acute viral hepatitis, cirrhosis, liver tuberculosis ( $p < 0.00001$ ), malaria ( $p < 0.003$ ) and early infection of schistosomiasis mansoni ( $p < 0.007$ ). Most of the cases in amoebic liver abscess had extremely high values of serum ferritin (Fig. 1). Only 30% (3 cases out of 10) of patients with early infection of schistosomiasis mansoni had serum ferritin values that were above the normal upper limit of  $253.58 \mu\text{g/l}$  defined as the mean  $+ 2$  S.D. (standard deviation) of the controls (Fig. 1).

## Discussion

The results of this study indicate that serum ferritin is above the normal upper limit in 100% of all patients with amoebic liver abscess, acute viral hepatitis, and liver tuberculosis. High values were found in all the cases in these groups, but less dramatically elevated values and even values within the normal upper limit were found in the cases of malaria, cirrhosis and early infection of schistosomiasis mansoni. Levels of serum transaminases and alkaline phosphatase are usually variable and of little diagnostic value in amoebic liver abscess (Sherlock, 1981; Datta et al., 1973). Our findings in acute viral hepatitis and cirrhosis where the serum ferritin was highly elevated in some cases, agree with those reported previously in patients with these liver diseases (Prieto et al., 1975; Zuyderhoudt et al., 1978).

The present study provides some evidence for the hypothesis that ferritinemia of acute, chronic liver diseases and diseases of liver involvement is largely derived from damaged hepatocytes. However, circulating ferritin is also depen-

dent on iron stores, but as it was previously pointed out (Prieto et al., 1975; Lundin et al., 1981), the high serum ferritin levels found in cirrhosis are no indication of iron stores.

The present data suggest that increased serum ferritin values are found not only in acute or chronic liver diseases but also in a number of tropical infectious or parasitic diseases which involve the liver.

A larger number of healthy persons and of patients with these diseases need to be studied for further statistical support. Moreover a prospective study may give more information as to the use of ferritin as a serum parameter of liver involvement in tropical parasitic diseases.

Addison G. M., Beamish M. R., Hales C. N. et al.: An immunoradiometric assay for ferritin in the serum of normal subjects and patients with iron deficiency and iron overload. *J. clin. Path.* 25, 326 (1972).

Cook J. D., Lipschitz D. A., Miles L. E. M. et al.: Serum ferritin as a measure of iron stores in normal subjects. *Amer. J. clin. Nutr.* 27, 681 (1974).

Datta D. V., Saha S., Samanta A. S. et al.: The clinical pattern and prognosis of patients with amoebic liver abscess and jaundice. *Digest. Dis.* 8, 887 (1973).

Dorrough R. L.: Amoebic liver abscess. *Sth. med. J.* 60, 305 (1967).

Grail A., Bates G., Ward M. et al.: Serum ferritin as a third marker in germ cell tumours. *Europ. J. Cancer clin. Oncol.* 18, 261 (1982).

Green R., Watson L. R., Saab G. A. et al.: «Normal» serum ferritin – a caution. *Blood* 50, 545 (1977).

Jacobs A., Worwood M.: Ferritin in serum: clinical and biochemical implications. *New Engl. J. Med.* 292, 951 (1975).

Jones P. A. E., Miller F. M., Worwood M. et al.: Ferritinaemia in leukaemia and Hodgkin's disease. *Brit. J. Cancer* 27, 212 (1973).

Lipschitz D. A., Cook J. D., Finch C. A.: A clinical evaluation of serum ferritin as an index of iron stores. *New Engl. J. Med.* 290, 1212 (1974).

Lundin L., Hallgren R., Birgegård G. et al.: Serum ferritin in alcoholics and the relation to liver damage, iron state and erythropoietic activity. *Acta med. scand.* 209, 327 (1981).

Mori W., Asakawa H., Taguchi T.: Anti-serum against leukemic cell ferritin as a diagnostic tool for malignant neoplasma. *J. nat. Cancer Inst.* 55, 513 (1975).

Nelson R., Chawla M., Connolly P.: Ferritin as an index of bone marrow iron stores. *Sth. med. J.* 71, 1481 (1978).

Niitsu Y., Kohgo Y., Yokota M. et al.: Radioimmunoassay of serum ferritin in patients with malignancy. *Ann. N.Y. Acad. Sci.* 259, 450 (1975).

Patel A. R., Shah P. C., Vohra R. M. et al.: Serum ferritin levels in hematologic malignant neoplasms. *Arch. Path. Lab. Med.* 104, 509 (1980).

Prieto J., Barry M., Sherlock S.: Serum ferritin in patients with iron overload and with acute and chronic liver disease. *Gastroenterology* 68, 525 (1975).

Sherlock S.: Hepatic amoebiasis. In: *Diseases of the liver and biliary system*, ed. by S. Sherlock, 6th ed., p. 431. Blackwell Scientific Publications, Oxford, 1981.

Tomoda H., Furusawa M., Seo Y. et al.: Measurement of serum ferritin in various digestive diseases by reversed passive hemagglutination using anti-human placental antiserum. *Jap. J. clin. Oncol.* 12, 9 (1982).

Walters G. O., Miller F. M., Worwood M.: Serum ferritin concentration and iron stores in normal subjects. *J. clin. Path.* 26, 770 (1973).

- Zucker S., Friedman S., Lysik R. M.: Bone marrow erythropoiesis in the anaemia of infection, inflammation and malignancy. *J. clin. Invest.* 53, 1132 (1974).
- Zuyderhoudt F. M. J., Boers W., Linthorst C. et al.: An enzyme-linked immunoassay for ferritin in human serum and rat plasma and the influence of the iron in serum ferritin on serum iron measurement during acute hepatitis. *Clin. chim. Acta* 88, 37 (1978).