

Zeitschrift: Acta Tropica
Herausgeber: Schweizerisches Tropeninstitut (Basel)
Band: 40 (1983)
Heft: 4

Artikel: Sowda-type onchocerciasis in Guatemala
Autor: Schwartz, D.A. / Brandling-Bennett, A.D. / Figueroa M., H.
DOI: <https://doi.org/10.5169/seals-313146>

Nutzungsbedingungen

Die ETH-Bibliothek ist die Anbieterin der digitalisierten Zeitschriften. Sie besitzt keine Urheberrechte an den Zeitschriften und ist nicht verantwortlich für deren Inhalte. Die Rechte liegen in der Regel bei den Herausgebern beziehungsweise den externen Rechteinhabern. [Siehe Rechtliche Hinweise.](#)

Conditions d'utilisation

L'ETH Library est le fournisseur des revues numérisées. Elle ne détient aucun droit d'auteur sur les revues et n'est pas responsable de leur contenu. En règle générale, les droits sont détenus par les éditeurs ou les détenteurs de droits externes. [Voir Informations légales.](#)

Terms of use

The ETH Library is the provider of the digitised journals. It does not own any copyrights to the journals and is not responsible for their content. The rights usually lie with the publishers or the external rights holders. [See Legal notice.](#)

Download PDF: 14.05.2025

ETH-Bibliothek Zürich, E-Periodica, <https://www.e-periodica.ch>

¹ Department of Parasitology, Institute of Medicine, Far Eastern University, Manila, Philippines

² Center for Infectious Diseases, Centers for Disease Control, Public Health Service, Atlanta, Georgia 30333, USA

³ Onchocerciasis Section, Division of Epidemiology, Public Health Services, Guatemala City, Guatemala

⁴ Department of Infectious and Parasitic Disease Pathology, and the World Health Organization Collaborating Center for the Histopathology of Filarial Infections of Man, Armed Forces Institute of Pathology, Washington, D.C. 20306, USA

Sowda-type onchocerciasis in Guatemala*

D. A. SCHWARTZ¹, A. D. BRANDLING-BENNETT², H. FIGUEROA M.³,
D. H. CONNOR⁴, D. W. GIBSON⁴

Summary

The usual pattern of onchocercal dermatitis in Africans and Guatemalans is a generalized and symmetrical dermatitis located on legs, arms and trunk. These patients appear to be anergic, with depressed immune responses and numerous microfilariae in the skin. In contrast, “sowda” is an unusual type of onchocercal dermatitis found in Yemenites and in a minority of African patients. Here the dermatitis is localized and asymmetrical – typically confined to one limb or one region of the body. Patients with sowda appear to be hyperergic, with active humoral and cellular immune responses; microfilariae are rare or absent. This study describes two Guatemalan patients with sowda-type dermatitis. The diagnosis in these two patients is based on the asymmetrical papular pruritic dermatitis, rare or absent microfilariae, a positive Mazzotti reaction, and histopathologic changes characteristic of the sowda-type onchocercal dermatitis.

Key words: sowda; onchocerciasis; Guatemala.

* This work was supported in part by the World Health Organization (WHO), Geneva, in part by the Centers for Disease Control (CDC), Atlanta, and in part by the Public Health Services of Guatemala (PHS/G). The opinions or assertions contained herein are the private views of the authors and are not to be construed as official or as reflecting the views of the WHO, CDC, PHS/G, Department of the Army, or Department of Defense.

Introduction

Infection of man by *Onchocerca volvulus* causes a spectrum of clinico-pathologic features (Connor and Neafie, 1976; Connor et al., 1970, 1983; Gibson and Connor, 1978; Gibson et al., 1976, 1980; Nelson, 1970; Duke et al., 1966). Dermatitis is a prominent feature of onchocerciasis and in Africans the dermatitis tends to be bilateral and symmetrical, most commonly involving thighs, shins, buttocks and lower trunk. In Central and South Americans, lesions are more common on the upper trunk, head, neck and arms (Figueroa, 1974, 1977; Salazar Mallén, 1974; Convit, 1974; Brandling-Bennett et al., 1981). Lymph nodes draining areas of inflamed skin are usually small and firm (Gibson and Connor, 1978).

Sowda, the feminine form of the Arabic *aswad* (meaning black), has been used for many years in some regions of Yemen to describe an unusual skin disease. Fawdry (1957) identified sowda as a manifestation of onchocerciasis and recently Connor et al. (1983) described clinical and histopathologic features of 18 Yemenites with sowda and concluded that sowda is a hyperergic form of onchocercal dermatitis. Sowda differs from the usual form of onchocercal dermatitis seen in Africans and in Central and South Americans in that it is asymmetrical – usually limited to one limb – which is dark, swollen and covered with scaly papules. Microscopically there is extensive and severe inflammation but microfilariae are rare.

Figueroa has reviewed onchocerciasis in Guatemala, and described a single patient who had clinical features which he described as “pseudo-sowda” (Figueroa, 1974, 1977). We report here two more patients in Guatemala with sowda-type dermatitis.

Material and Methods

Punch biopsy specimens of skin (6-mm diameter) were fixed in formalin, embedded in paraffin, sectioned at 5 μ m thickness, and stained with the H&E, Giemsa and Russell-Movat procedures as previously described (Connor et al., 1970, 1983). Skin snips were taken with a Walser-type sclerocorneal punch and incubated in NCTC-135 tissue culture medium for 24 hours, and microfilariae were counted.

Case Reports

Patient 1. – A 28-year-old Guatemalan Indian male, who had lived in an area endemic for onchocerciasis for 18 years, was examined by one of us during epidemiologic studies (Brandling-Bennett et al., 1981). He had a sowda-like dermatitis with papular and hyperpigmented lesions and excoriations on the buttocks, abdomen, and one leg (Figs. 1 and 2). In the past, two onchocercal nodules had been removed from the head, but he now had no detectable nodules. Skin snips of shoulders and buttock revealed no microfilariae.

Microscopically the biopsy specimens of abdomen and buttock revealed focal hyperkeratosis, parakeratosis, and acanthosis with some follicular plugging (Fig. 3). The dermal papillae were scarred, the dermis was edematous, and dermal fibroblasts were large and numerous. Melanin was

in histiocytes in the upper dermis, and small blood vessels were dilated and tortuous. Elastic fibers were reduced in number. Lymphocytes, plasma cells, histiocytes, eosinophils and occasional mast cells were concentrated around blood vessels and appendages. In areas of maximal inflammation, eosinophils were degranulated. A single microfilaria of *Onchocerca volvulus* was between the collagen fibers in the upper dermis (Fig. 4). It was not degenerating and was not located in a focus of inflammation.

Patient 2. – A 34-year-old male Guatemalan farm laborer lived on Finca San Rafael, a coffee plantation with endemic onchocerciasis. He had a severe maculopapular dermatitis on the left arm, forearm (Fig. 5), wrist and left anterior chest. Most of the macules were scaling. Some were crusting, and others were hypopigmented. They varied from 1 to about 20 mm across. Fifty mg of diethylcarbamazine (DEC; Hetrazan) by mouth caused intense itching of arms, face and trunk within a few minutes. Itching was most severe on the left arm and anterior chest.

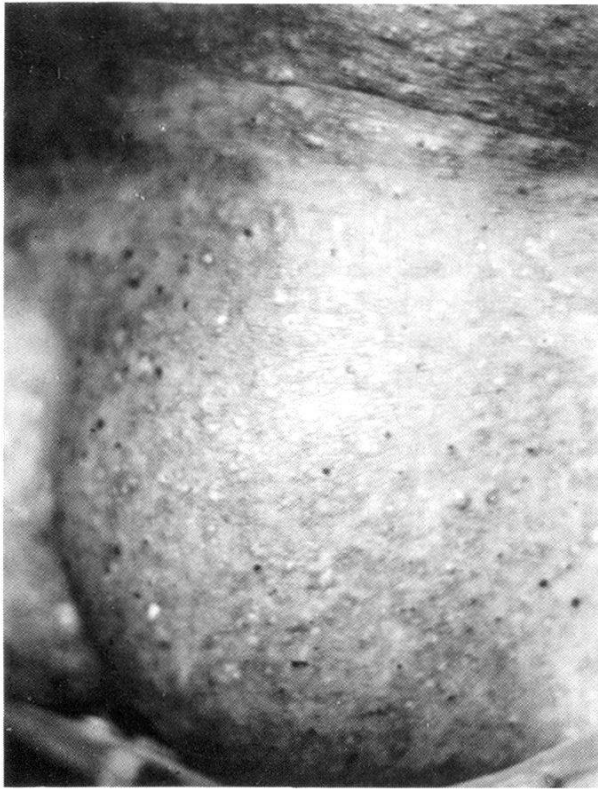A biopsy specimen of left forearm, before treatment, revealed acanthosis, follicular plugging, focal parakeratosis and hyperkeratosis (Fig. 6). Approximately 20% of the dermis contained inflammatory cells that extended into the panniculus, where eosinophils predominated. Microfilariae were not found.

Discussion

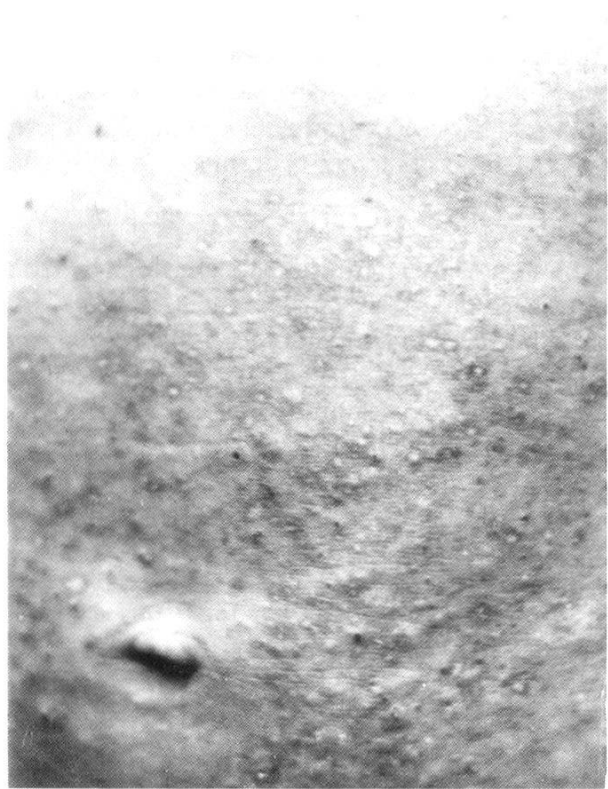The findings which characterize sowda – edematous dark skin with papules and itching confined to one limb or one region of the body – are present in both patients and both biopsy specimens were typical of onchocercal dermatitis (Connor et al., 1983). In addition the special microscopic features which characterize sowda – hyperkeratosis, parakeratosis, acanthosis, follicular plugging and voluminous inflammatory cell infiltrate throughout the dermis – were also present. Finally microfilariae are rare to the point of being nearly impossible to find in some patients. The single microfilaria in patient 1 was found only after prolonged search; and none was found in patient 2, even after a search of 30 slides – but we are certain of the diagnosis because of the typical Mazzotti reaction. These two patients are the second and third with sowda to be reported from Guatemala.

Connor et al. (1983) suggested that sowda in Yemenites was an hypergic reaction to degenerating microfilariae. If so, most microfilariae might be destroyed soon after emerging from the female worm. This would reduce the number of microfilariae appearing in the dermis and also explain the limited, asymmetrical dermatitis characteristic of sowda. In contrast, the diffuse onchocerciasis in Africans may be a consequence of immune suppression. Africans with onchocerciasis respond poorly to heterologous vaccines for yellow fever, mycobacterial antigens, and tetanus toxoid (Buck et al., 1969, 1971; Prost, 1980). They also respond poorly to homologous onchocercal antigens in in vitro assays for cellular and humoral immunity (Bartlett et al., 1978; Ngu, 1978).

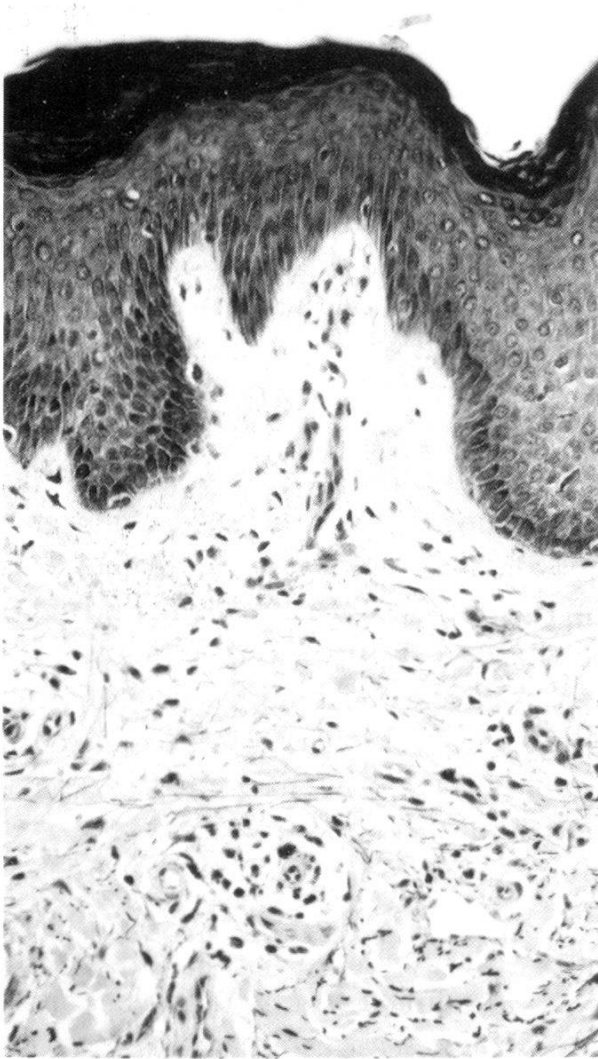Supporting these views is a study by Gibson and Connor (1978) of the histopathologic changes in the lymph nodes from 34 patients with onchocercal lymphadenitis. Lymph nodes from Africans with long-standing onchocerciasis are small and hard, having atropic follicles with almost complete replacement of lymphoid tissue by fibrous scar – all consistent with a depressed immune



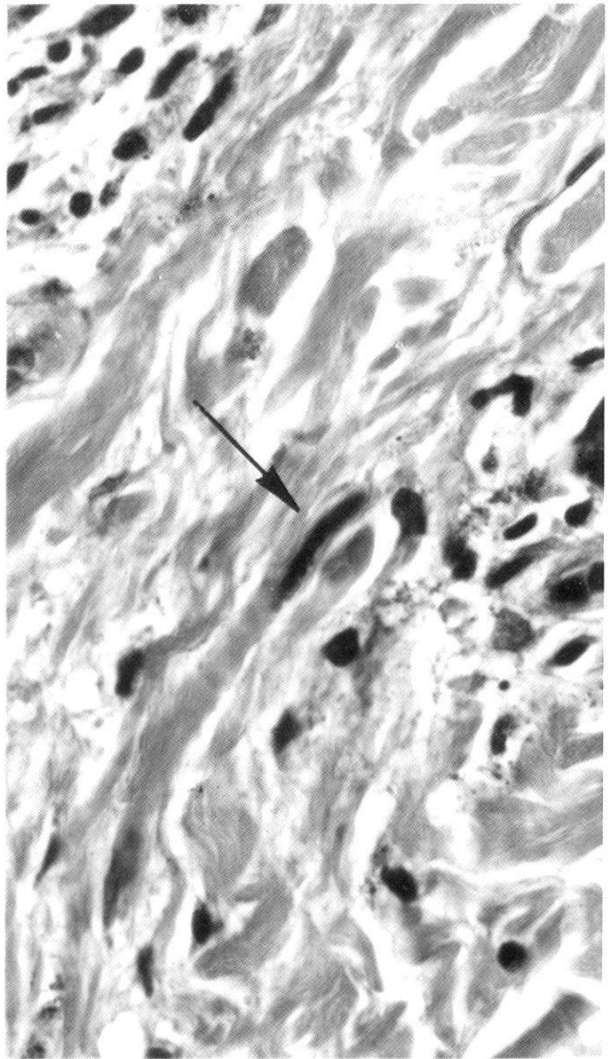
1



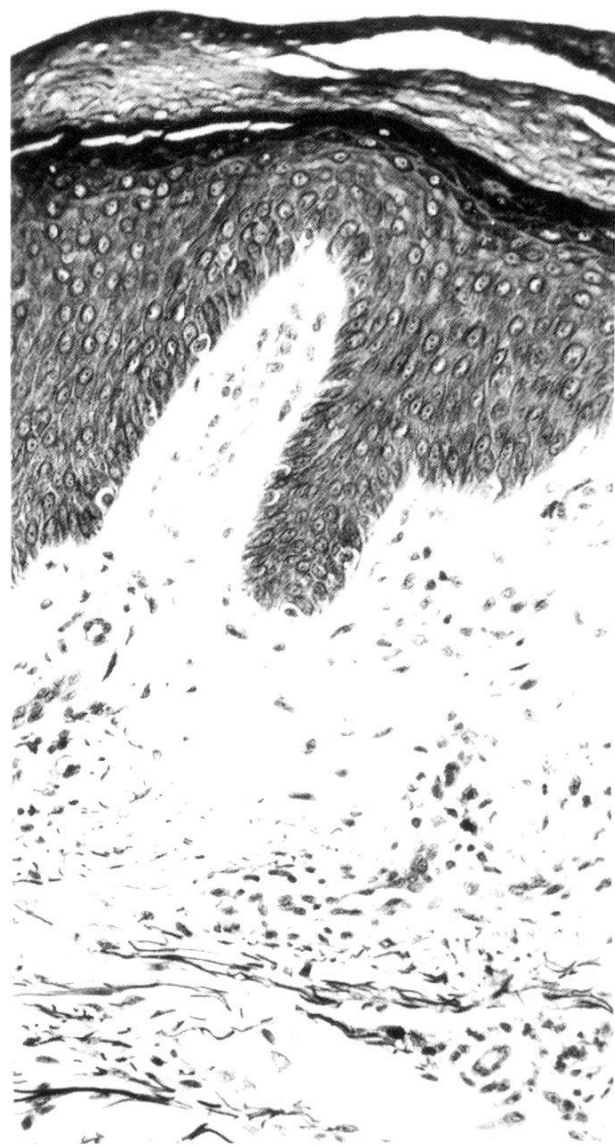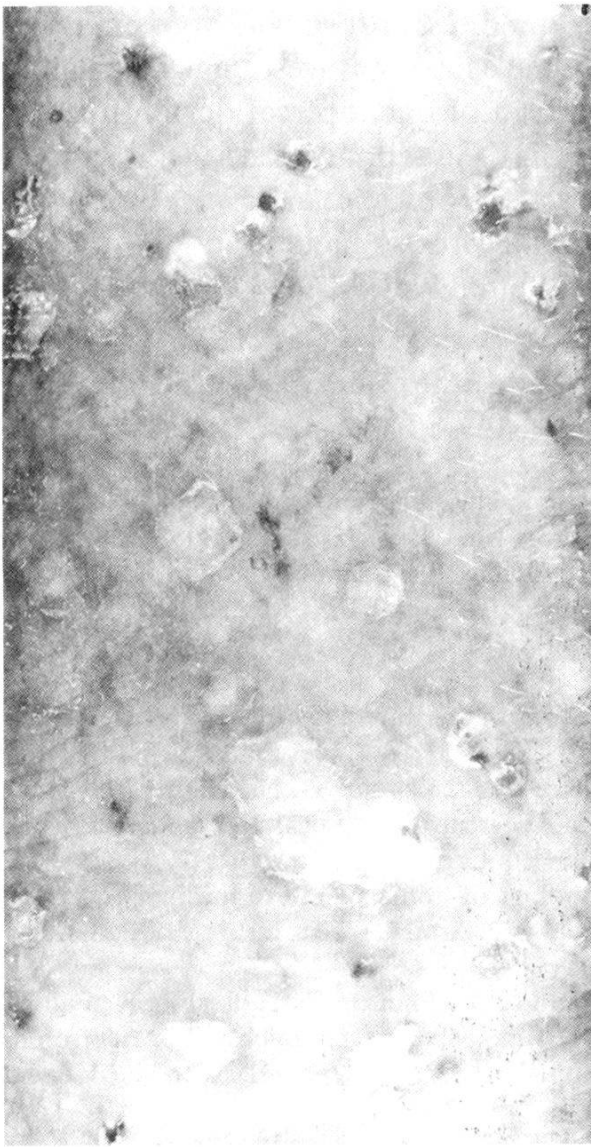
2



3



4



6

Fig. 1. Skin of buttock of patient 1 with swelling, hyperpigmentation and papules. Some of the papules are crusted and scaling (AFIP Neg. 81-18244).

Fig. 2. Skin of abdomen of patient 1 with alteration in pigmentation and papules (AFIP Neg. 81-18240).

Fig. 3. Skin of lower abdomen of patient 1, showing hyperkeratosis, acanthosis, and scarring of dermal papillae. Plugging of a follicle is present, but not shown in this field. There is also a diffuse inflammatory cell infiltrate and a loss of elastic fibers in the upper dermis. The dermal blood vessels are tortuous, and the lymphatics are dilated. Microfilariae are not present in this field. Movat, 160 \times (AFIP Neg. 81-18229).

Fig. 4. Upper dermis in abdominal skin of patient 1. Note tangential section of a microfilaria of *O. volvulus* (arrow). It appears intact and viable and is not surrounded by leukocytes. Hematoxylin and eosin, 630 \times (AFIP Neg. 81-18232).

Fig. 5. Skin of forearm just above wrist of patient 2, showing papular dermatitis with blood-tinged scales and crusts. Actual size (AFIP Neg. 72-17116).

Fig. 6. Skin of forearm on patient 2 before treatment with DEC. Hyperkeratosis, acanthosis, fibrosis and scarring of the dermal papillae, and destruction of elastic fibers can be seen. Present, but not shown in this field, are follicular plugging and focal parakeratosis. The inflammatory infiltrate extends through the dermis and into the panniculus. Movat, 160 \times (AFIP Neg. 82-12490).

response. In contrast, lymph nodes from Yemenites with sowda were enlarged and soft and had marked follicular hyperplasia. These features suggest an active immune response. Although the hypergic form of onchocercal dermatitis was first recognized in Yemen, we now know that Guatemalans as well as some patients in Africa have the same type of reaction (Wolfe et al., 1974; Bartlett et al., 1978; Ngu, 1978; Connor et al., 1983). The precise factors underlying this unusual expression of onchocerciasis are still unknown.

- Anderson J., Buck A. A., Budden F. H., Connor D. H., Fuglsang H., Picq J. J., Rolland A., Waddy B. B.: Onchocerciasis: symptomatology, pathology, diagnosis, ed. by A. A. Buck, 80 p. World Health Organization, Geneva 1974.
- Bartlett A., Turk J., Ngu J., Mackenzie C. D., Fuglsang H., Anderson J.: Variation in delayed hypersensitivity in onchocerciasis. *Trans. roy. Soc. trop. Med. Hyg.* 72, 372–377 (1978).
- Brandling-Bennett A. D., Anderson J., Fuglsang H., Collins R.: Onchocerciasis in Guatemala. Epidemiology in fincas with various intensities of infection. *Amer. J. trop. Med. Hyg.* 30, 970–981 (1981).
- Buck A. A., Anderson R. I., Kawata K., Hitchcock J. C. jr.: Onchocerciasis: some new epidemiologic and clinical findings. Results of an epidemiologic study in the Republic of Chad. *Amer. J. trop. Med. Hyg.* 18, 217–230 (1969).
- Buck A. A., Anderson R. I., Colston J. A. C., Wallace C. K., Connor D. H., Harman L. E. jr., Donnor M. W., Ganley J. P.: Microfilaruria in onchocerciasis: a clinical and epidemiological follow-up study in the Republic of Chad. *Bull. Wld Hlth Org.* 45, 353–369 (1971).
- Connor D. H., Neafie R. C.: Onchocerciasis. In: *Pathology of tropical and extraordinary diseases*, ed. by C. H. Binford and D. H. Connor, vol. 2, p. 360–372. Armed Forces Institute of Pathology, Washington, D.C. 1976.
- Connor D. H., Morrison N. E., Kerdel-Vegas F., Berkoff H. A., Johnson F., Tunnicliffe R., Failing F. C., Hale L. N., Lindquist K., Thornbloom W. (Dr. and Mrs.), McCormick J. B., Anderson S. L.: Onchocerciasis. Onchocercal dermatitis, lymphadenitis, and elephantiasis in the Ubangi territory. *Hum. Path.* 1, 553–597 (1970).
- Connor D. H., Gibson D. W., Neafie R. C., Merighi B., Buck A. A.: Sowda – onchocerciasis in North Yemen: a clinicopathologic study of 18 patients. *Amer. J. trop. Med. Hyg.* 32, 123–137 (1983).
- Convit J.: Onchocerciasis in Venezuela. In: *Research and control of onchocerciasis in the Western Hemisphere*, ed. by M. Martins da Silva. Pan Amer. Hlth Org. Sci. Publ. 298, 105–111 (1974).
- Duke B. O. L., Lewis D. J., Moore P. J.: Onchocerca-Simulium complexes. I. Transmission of forest and Sudan-savanna strains of *Onchocerca volvulus*, from Cameroon, by *Simulium damnosum* from various West African bioclimatic zones. *Ann. trop. Med. Parasit.* 30, 318–326 (1966).
- Fawdry A. L.: Onchocerciasis in south Arabia. *Trans. roy. Soc. trop. Med. Hyg.* 51, 253–256 (1957).
- Figueroa M. H.: Robles' disease (American onchocerciasis) in Guatemala. In: *Research and control of onchocerciasis in the Western Hemisphere*, ed. by M. Martins da Silva. Pan Amer. Hlth Org. Sci. Publ. 298, 100–104 (1974).
- Figueroa M. H.: Enfermedad de Robles una lesión cutánea poco frecuente. *Rec. Col. Méd. Guat.* 28, 81–84 (1977).
- Gibson D. W., Connor D. H.: Onchocercal lymphadenitis: clinicopathologic study of 34 patients. *Trans. roy. Soc. trop. Med. Hyg.* 72, 137–154 (1978).
- Gibson D. W., Connor D. H., Brown H. L., Fuglsang H., Anderson J., Duke B. O. L., Buck A. A.: Onchocercal dermatitis: ultrastructural studies of microfilariae and host tissues, before and after treatment with diethylcarbamazine (Hetrazan). *Amer. J. trop. Med. Hyg.* 25, 74–87 (1976).

- Gibson D. W., Heggie C., Connor D. H.: Clinical and pathologic aspects of onchocerciasis. In: Pathology annual: 1980, ed. by S. C. Sommers and P. P. Rosen, vol. 15, part 2, p. 195–240. Appleton-Century-Crofts, New York 1980.
- Nelson G. S.: Onchocerciasis. *Advanc. Parasit.* 8, 173–224 (1970).
- Ngu J. L.: Immunological studies on onchocerciasis: varying skin hypersensitivity and leucocyte migration inhibition in a clinical spectrum of disease. *Acta trop. (Basel)* 35, 269–279 (1978).
- Prost A.: Progress achieved in the epidemiological approach to onchocerciasis and problems still unsolved. Report to the Third Scientific Working Group on Epidemiology, Geneva, 29 September to 1 October 1980, 18 p. UNDP/World Bank/WHO Special Programme for Research and Training in Tropical Diseases. World Health Organization, Geneva 1980.
- Salazar Mallén M.: Onchocerciasis in Mexico. In: Research and control of onchocerciasis in the Western Hemisphere, ed. by M. Martins da Silva. Pan Amer. Hlth Org. Sci. Publ. 298, 112–115 (1974).
- Wolfe M. S., Petersen J. L., Neafie R. C., Connor D. H., Purtilo D. T.: Onchocerciasis presenting with swelling of limb. *Amer. J. trop. Med. Hyg.* 23, 361–368 (1974).

