

Peripheral lymphadenopathy in Nigeria

Autor(en): **Oluwole, S.F. / Odesanmi, W.O. / Kalidasa, A.M.**

Objektyp: **Article**

Zeitschrift: **Acta Tropica**

Band (Jahr): **42 (1985)**

Heft 1

PDF erstellt am: **22.07.2024**

Persistenter Link: <https://doi.org/10.5169/seals-313457>

Nutzungsbedingungen

Die ETH-Bibliothek ist Anbieterin der digitalisierten Zeitschriften. Sie besitzt keine Urheberrechte an den Inhalten der Zeitschriften. Die Rechte liegen in der Regel bei den Herausgebern. Die auf der Plattform e-periodica veröffentlichten Dokumente stehen für nicht-kommerzielle Zwecke in Lehre und Forschung sowie für die private Nutzung frei zur Verfügung. Einzelne Dateien oder Ausdrucke aus diesem Angebot können zusammen mit diesen Nutzungsbedingungen und den korrekten Herkunftsbezeichnungen weitergegeben werden. Das Veröffentlichen von Bildern in Print- und Online-Publikationen ist nur mit vorheriger Genehmigung der Rechteinhaber erlaubt. Die systematische Speicherung von Teilen des elektronischen Angebots auf anderen Servern bedarf ebenfalls des schriftlichen Einverständnisses der Rechteinhaber.

Haftungsausschluss

Alle Angaben erfolgen ohne Gewähr für Vollständigkeit oder Richtigkeit. Es wird keine Haftung übernommen für Schäden durch die Verwendung von Informationen aus diesem Online-Angebot oder durch das Fehlen von Informationen. Dies gilt auch für Inhalte Dritter, die über dieses Angebot zugänglich sind.

¹ Department of Surgery,

² Department of Morbid Anatomy and Forensic Medicine, Faculty of Health Sciences,
University of Ife, Ile-Ife, Nigeria

Peripheral lymphadenopathy in Nigeria

S. F. OLUWOLE¹, W. O. ODESANMI², A. M. KALIDASA²

Summary

An analysis of 294 enlarged peripheral lymph node biopsies in Ife, Nigeria, revealed that the underlying disease in 51.7% was chronic inflammation while malignant diseases accounted for 48.3%. The order of frequency of the lesions was reactive hyperplasia (29.3%), metastatic cancer (24.5%), malignant lymphoma (23.8%), tuberculosis (15.6%) and toxoplasmosis (3.7%). One-third of the metastases were of undetermined origin. The neck which accounted for 53% of the biopsies, was the most frequent site for tuberculous adenitis, toxoplasmic lymphadenitis, and malignancies. The axilla was involved in 15% of the cases and was the most common site for metastatic breast carcinoma. The inguinal lymph nodes were also involved in 24% of the cases and had the highest occurrence of melanoma, reactive hyperplasia and parasitic granuloma. The habit of bare-foot walking leading to repeated trauma and infection is implicated in the high incidence of inguinal node reactive hyperplasia. This study demonstrates that lymph node malignancies and chronic granulomatous infections present a problem of increasing diagnostic and therapeutic importance and furthermore, it emphasizes that physicians in Nigeria should consider toxoplasmosis in the differential diagnosis of peripheral lymphadenopathy.

Key words: reactive hyperplasia; tuberculous adenitis; toxoplasmic lymphadenitis; filarial parasitic granuloma; metastatic cancer; malignant lymphoma.

Introduction

Patients who have persistent, palpable superficial lymph nodes without any apparent cause present a diagnostic challenge and a therapeutic problem.

Correspondence: Soji F. Oluwole, M. D., Department of Surgery, Faculty of Health Sciences, University of Ife, Ile-Ife, Nigeria

The fear of the patient and physician that the mass may be malignant is heightened if the lymph node increases in size when the patient is under observation. The dilemma of deciding if the enlarged lymph node is malignant or not may be resolved by an excisional biopsy as part of the diagnostic work-up of the patient. This will allow the physician to make an early diagnosis and treat the underlying disease.

This problem is further complicated in the tropics by a variety of factors including the attitude of the people towards aetiology of diseases, the continued exposure to parasitic and chronic granulomatous diseases, the socio-economic status of the patient, the availability of diagnostic facilities and the location of such a palpable lymph node. The latter factor may explain the differences in the approach to the management of neck and groin lymph node enlargement in the tropics. The treatment of an enlarged cervical lymph node may be aggressive because of the suspicion of malignant lymphoma while that in the groin is given a cautious and conservative approach because the great majority of enlarged inguinal nodes are inflammatory. The habit of barefoot walking subjects the feet to constant trauma, ulceration and infection with the resultant ascending lymphangitis and enlarged groin lymph nodes.

Since the persistence of palpable enlarged superficial lymph nodes raises the question of cancer, it is therefore necessary to study and define the pattern of distribution of diseases that may cause this clinical condition in tropical countries. Unfortunately, the literature from the tropics is scant on this topic. This retrospective study was therefore carried out to examine the pathologic conditions which cause peripheral lymphadenopathy in Nigerians and to report the anatomic sites where such diseases are commonly found. Our findings are based on the review of 294 cases of superficial lymph node biopsies seen in the Morbid Anatomy Department of Ife University Teaching Hospital, Ile-Ife, Nigeria. The hospital serves a homogenous population of people who are predominantly of Yoruba ethnic group and living in the Western States of Nigeria.

Materials and Methods

The biopsy reports of 294 patients with superficial lymph node enlargement as the primary presenting symptom seen at Ife University Teaching Hospital between 1973 and 1982 were reviewed for age, sex, underlying disease, primary source of metastatic disease and the anatomic distribution of biopsy sites. Most patients had excisional lymph node biopsies for small lesions while incisional biopsies were done for large masses. The reasons for lymph node biopsies included suspected malignant lymphoma, secondary malignant lesions, tuberculosis, and enlarged lymph nodes that were initially believed to be secondary to inflammatory disease but which failed to respond to antibiotic treatment. The metastatic disease of determinate origin was documented from either biopsy or surgical removal of the primary disease and those whose primary sites were not found were classified as metastases of undetermined origin.

Results

Underlying disease

Table 1 shows the pathologic distribution of the underlying diseases in the 294 biopsies. Metastatic cancer and malignant lymphoma were the most common lesion for which biopsy was done. The descending order of frequency in which the diseases were encountered was non-specific reactive hyperplasia, 86 cases (29.25%); metastatic cancer, 72 (24.5%); malignant lymphoma, 70 (23.8%); tuberculosis, 46 (15.6%); toxoplasmosis, 11 (3.7%), and filarial parasitic granuloma, 9 (3%). The 70 malignant lymphoma consisted of 21 cases of Hodgkin's disease, 9 of Burkitt's lymphoma and 40 of other malignant lymphomas.

Table 1. Distribution of underlying diseases, age and sex of 294 cases of superficial lymph node biopsies

Pathologic diagnosis	No. of cases	Percent	Mean age in years (range)	Male/female ratio
Tuberculosis	46	15.65	23.4 (4-60)	19/27
Toxoplasmosis	11	3.74	31.0 (21-66)	6/5
Filarial parasitic granuloma	9	3.06	28.4 (20-60)	6/3
Non-specific reactive hyperplasia	86	29.25	28.6 (1/4-75)	65/21
Metastatic cancer	72	24.49	49 (18-75)	29/43
Malignant lymphomas	70	23.81	32.5 (1/2-80)	48/22
Total	294	100	33.8 (1/4-80)	173/121

Age and sex distribution

The study group comprised 173 men and 121 women with a sex ratio of approximately three males to two females. The ages ranged from 3 months to 80 years with a mean of 33.8 years. There were 46 patients with tuberculous adenitis, 19 men and 27 women with a mean age of 23.4 years. This showed a preponderance of females to males by a ratio of three to two. The sex ratio was approximately one for the eleven patients who had toxoplasmosis. Their mean age was 31 years. The 86 patients with non-specific reactive hyperplasia consisted of 65 men and 21 women with a mean age of 29 years. The patients with metastatic disease comprised 29 men and 43 women with a mean age of 49 years. The mean age of the 70 patients (48 men and 22 women) with malignant lymphoma was 32.5 years. It appears that malignant lymphoma is more frequent in the younger age group than metastatic diseases.

Table 2. Site of involvement and source of lymph node metastasis

Source	Lymph node site			No. of cases	Male/ female ratio
	cervical	axillary	inguinal		
Breast	3	15	–	18 (25.00%)	0/18
Malignant melanoma	–	2	10	12 (16.67%)	8/4
Stomach	4	–	–	4 (5.56%)	2/2
Ano-rectum	–	–	3	3 (4.16%)	2/1
Skin carcinoma	2	–	1	3 (4.16%)	2/1
Salivary gland	2	–	–	2 (2.77%)	0/2
Pancreas	2	–	–	2 (2.77%)	2/0
Lung	1	–	–	1 (1.39%)	1/0
Thyroid	1	–	–	1 (1.39%)	0/1
Prostate	–	–	1	1 (1.39%)	1/0
Undetermined	17	4	4	25 (34.72%)	11/14
Total	32	21	19	72 (100%)	29/43

Metastasis to lymph nodes

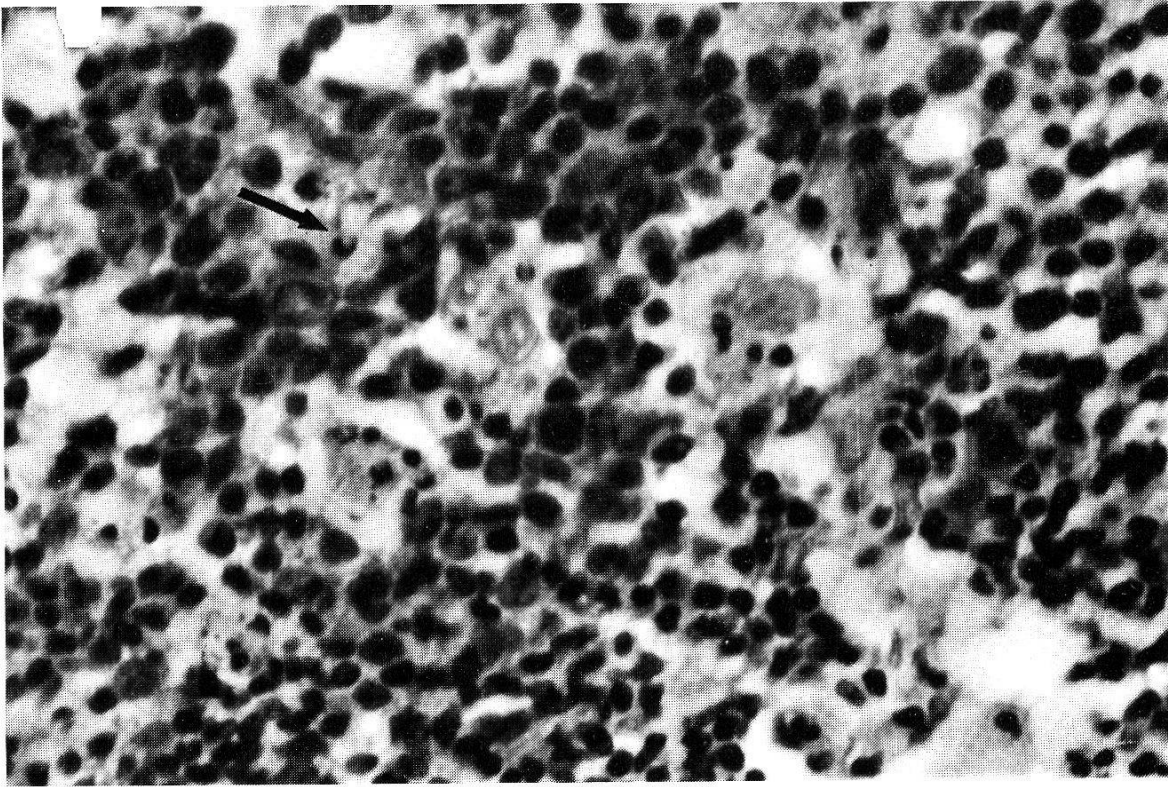
Table 2 summarizes the sites of involvement and the primary source of the 72 cases of metastatic disease. The lesions comprised 18 breast tumours, 12 malignant melanoma, 4 of gastric cancer, 3 each of anorectal carcinoma and skin cancer respectively, 2 each of pancreas and salivary gland carcinoma, and a case each of lung, thyroid gland and prostatic carcinoma.

Metastases of undetermined origin

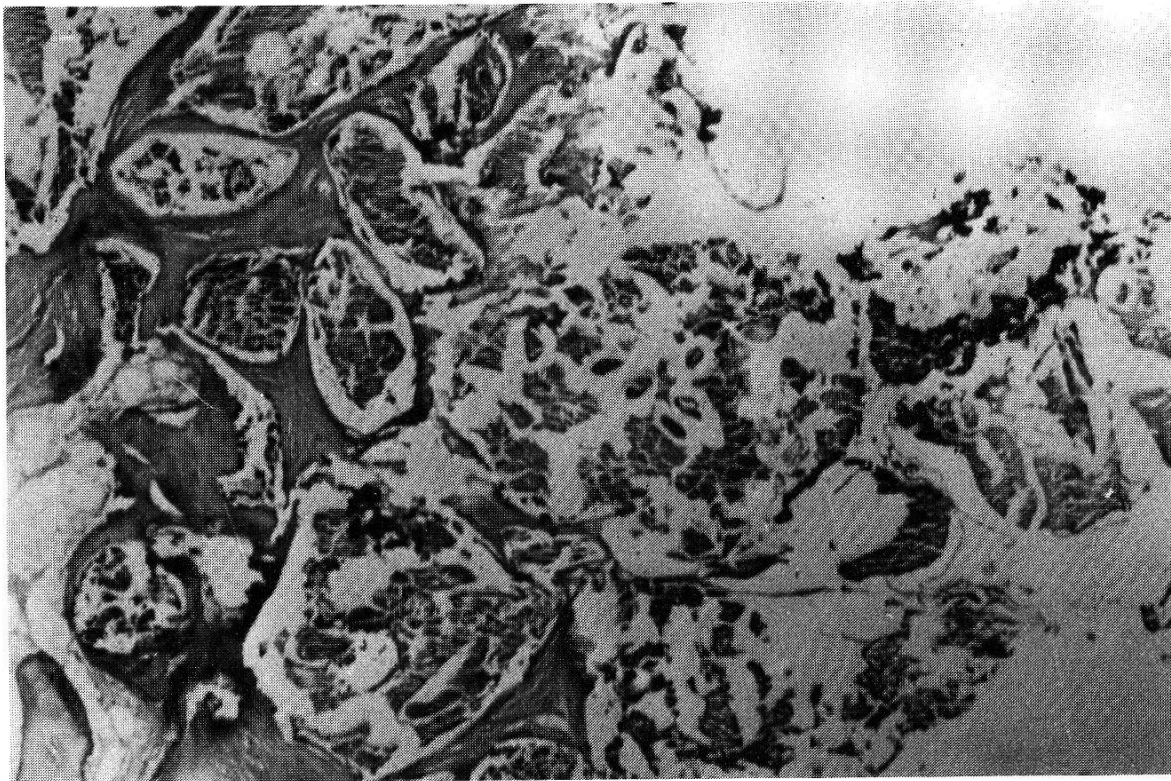
There were 25 metastases of unknown origin out of the 72 metastatic lesions in the series. Seventeen of these lesions were found in the neck while four cases were found in the axilla and groin respectively. The histologic distribution of the metastases without apparent primary sources was well differentiated adenocarcinoma, 7 cases; anaplastic carcinoma, 8; squamous cell carcinoma, 5; mucin secreting adenocarcinoma, 2; and a case each of adenocystic carcinoma, metaplastic carcinoma, and leiomyosarcoma.

Non-specific reactive hyperplasia

The histopathology of the group of lymph nodes diagnosed as non-specific reactive hyperplasia is variable. The histologic findings include hypertrophic lymphoid follicles with large clear reactive centres containing histiocytes, focal areas of necrosis, dilated sinuses, and diffuse fibrosis of the medullary zone with distortion of the node architecture. This picture is characterised by a predominance of either histiocytic hyperplasia, follicular hyperplasia or follicular atrophy with marked fibrosis. 48 cases (55.8%) showed predominance of histiocytic



1



2

Fig. 1. Section of lymph node showing clusters of histiocytes and viable toxoplasma (arrow). H & E, $\times 210$.

Fig. 2. Section of lymph node showing dilated lymphatic channels with adult forms of *Wuchereria bancrofti* (H & E, $\times 21$).

hyperplasia while 28 (32.6%) and 10 cases (11.6%) showed follicular atrophy with fibrosis and follicular hyperplasia respectively.

Toxoplasmic lymphadenitis

The histologic findings supporting the diagnosis of toxoplasmosis in all the eleven cases include preservation of the normal lymph node architecture, reactive follicular hyperplasia associated with the presence of increased reticular lymphoblasts and the presence of clusters of epithelioid histiocytes in the cortical and paracortical zones. Histiocytes were seen in the germinal centres. A lymph node had cysts in the paracortical zone while three of the lymph nodes revealed free forms of *Toxoplasma gondii* as illustrated in Fig. 1. The first five cases showed high serum antibody titres to *Toxoplasma gondii* which correlated with histological findings. Unfortunately the last six of the eleven cases had no serological confirmation of the disease because we had no reagent and the diagnosis was based solely on the pathology report. It is, however, noteworthy that the response to treatment in all the cases was impressive.

Parasitic granuloma

The lymph nodes diagnosed as parasitic granuloma had large amounts of fibrinoid material with fibrosis, hyalinization and calcification – and were sparsely infiltrated by eosinophils. It was not possible to be specific about the parasite that caused the lesion in most of the lymph nodes except in four cases where there were dilated lymph channels containing adult *Wuchereria bancrofti* filaria worms (Fig. 2). Three of the groin lymph nodes showed granuloma composed of dense whorled fibrous tissue with areas of calcification suggestive of *Onchocerca volvulus* infestation.

Site of involvement

Table 3 shows the distribution of the diseases to the various superficial lymph nodes. The order of frequency of involvement was cervical, inguinal and axillary lymph nodes.

Cervical lymph nodes

One hundred and fifty-two (51.7%) of the 294 biopsies were from the cervical lymph nodes. The lesions found in the neck were 53 cases of malignant lymphoma, 32 of metastatic cancer, 35 of tuberculosis, 23 of non-specific reactive hyperplasia and 9 of toxoplasmosis. The cervical lymph node region was the most common site involved in lymphoma, metastases, tuberculosis and toxoplasmosis. It is also noteworthy that the neck was the most frequent site for metastases from the stomach, pancreas, lung, thyroid, salivary gland and occult carcinoma (Table 2).

Table 3. Anatomic distribution of biopsy sites

Lesion	Lymph node biopsy sites					Total
	subman- dibular	cervical	axillary	inguinal	unspec- ified	
Tuberculosis	1	35	6	4	—	46
Toxoplasmosis	—	9	1	1	—	11
Filarial parasitic granuloma	—	—	—	6	3	9
Non-specific reactive hyperplasia	—	23	8	36	19	86
Metastatic cancer	—	32	21	19	—	72
Hodgkin's disease	—	19	1	1	—	21
Non-Hodgkin's lymphoma .	3	34	8	4	—	49
Total	4 (1.36%)	152 (51.7%)	45 (15.31%)	71 (24.15%)	22 (7.48%)	294 (100%)

Axillary lymph nodes

Forty-five (15.3%) of the biopsies were from the axilla and comprised 21 metastatic diseases, 9 malignant lymphomas, 6 of tuberculous adenitis, 8 of reactive hyperplasia and 1 case of toxoplasmosis. Fifteen of the 21 metastatic tumours in the axilla were from the breast and the others were 2 cases of malignant melanoma and 4 occult carcinomas.

Inguinal lymph nodes

The 71 inguinal node biopsies comprised 36 of reactive hyperplasia, 19 of metastatic tumours, 5 malignant lymphomas, 6 of filarial parasitic granuloma, 4 of tuberculosis and 1 case of toxoplasmosis. The metastases in the groin were 10 cases of malignant melanoma, 3 ano-rectal carcinoma and 4 of occult cancer, and 1 case each of prostatic and skin carcinoma. Of importance is the finding that ten of the 12 malignant melanoma lesions were found in the inguinal nodes. The 6 filarial parasitic granulomas comprised 3 of *Wuchereria bancrofti* and 3 of *Onchocerca volvulus*.

Other sites

Four lesions, 1 case of tuberculosis and 3 of malignant lymphoma, were found in the submandibular lymph nodes. The sites of biopsy were not known in 22 cases which consisted of 19 non-specific reactive hyperplasia and 3 of parasitic granuloma.

Discussion

The apparent enlargement of a localized superficial lymph node in the absence of a primary disease remains a diagnostic and therapeutic dilemma to the physician. Palpable superficial lymph nodes are usually secondary to infec-

tions or malignancies of the lymphoid tissue and it is a well established practice to biopsy such nodes. Numerous reports (Attiyeh et al., 1977; Berg et al., 1973; Jesse et al., 1973) have demonstrated the usefulness of lymph node biopsy as a diagnostic tool in the management as well as in predicting the prognosis of malignant diseases. This report analyzes the aetiological factors responsible for enlargement of superficial lymph nodes in Nigeria.

The findings demonstrate that the underlying lesion in 51.7% of the lymph node biopsies was chronic inflammation while malignant diseases accounted for 48.3%. Non-specific reactive hyperplasia accounted for 29.3% of the 294 cases which is equivalent to 56.7% of the inflammatory lesions. The observation that a great majority of patients with reactive hyperplasia had inguinal adenopathy was not surprising because this represents the penalty that is paid for barefoot walking in our community. This habit leads to repeated trauma and infection of the foot with the sequelae of chronic inflammation and fibrosis of the regional lymph nodes. Similarly it is observed that the majority of the 23 patients with reactive hyperplasia of the neck lymph nodes were children who probably had lymphadenitis as a sequela of upper respiratory tract infection. Excisional lymph node biopsy is only undertaken in children when either the palpable lymph node continues to enlarge after antibiotic treatment or when a solitary node is found in the absence of any associated adenopathy or evidence of primary disease. In such a situation, the biopsy is carried out to rule out malignancy or chronic granulomatous inflammatory disease.

Involvement of lymph nodes is the commonest site for non-respiratory tuberculosis. Thirty-six of the 46 cases of lymph node tuberculosis involved the neck while the others were found in the axilla and groin. The mean age of patients with tuberculous adenitis was 23 years. These observations confirm other reports (Farer et al., 1979; Fraser, 1965; Raz and Haas, 1983) which indicate that the neck is the most frequent site for extra-pulmonary tuberculosis and that cervical node tuberculosis is most common in children and young people. The preponderance of the disease in females presents a health problem of importance in the tropics where babies are usually breast fed by their mothers. This fact may partially explain the high incidence of the disease in children.

Toxoplasmosis is relatively rare in Nigeria compared with such protozoal infections like malaria and amoebiasis. The criteria for histopathologic diagnosis of lymph node toxoplasmosis in our patients are based on previous reports (Dorfman and Remington, 1973; Stansfeld, 1961). The pathologic findings include reactive follicular hyperplasia associated with the presence of irregular clusters of epithelioid histiocytes located in the cortical and paracortical zones. The epithelioid cells are frequently seen within the germinal centres. Occasionally free forms of *Toxoplasma gondii* may be seen in the paracortical zones of the lymph nodes (Fig. 1). All the five cases tested for serum antibody *Toxoplasma gondii* demonstrated high titres. As earlier pointed out, we had limited reagents for the serological tests and were unable to examine all our patients for

Toxoplasma antibody. The diagnosis of toxoplasmic lymphadenitis was therefore based on histologic findings in all the eleven cases. Of significance is the observation that all the patients responded to treatment with a combination of pyrimethamine and sulphonamide. It is, however, useful to add that in ideal situations, the pathologic diagnosis of toxoplasmosis must be complimented with either animal inoculation or serological tests to detect specific antibody to *Toxoplasma gondii*. The 3.74% incidence of toxoplasmosis in 294 lymph node biopsies suggests that toxoplasmic lymphadenitis is not very rare in this community as demonstrated by the recent report (Adeiga and Ahmed, 1983) from Lagos, Nigeria, which indicates that 40% of pregnant women tested for *Toxoplasma gondii* were seropositive. The present study therefore emphasizes the fact that acute acquired toxoplasmosis is one of the causes of enlarged lymph node in young adults in Nigeria.

Parasitic infections are endemic in tropical Africa. Of the parasitic filarial worms described in man, *Wuchereria bancrofti*, *Loa loa* and *Onchocerca volvulus* are commonly encountered in clinical practice in Nigeria. The microfilariae of these worms may infest the lymph nodes during their transport through the blood stream and lymphatics. This is particularly true for *Wuchereria bancrofti* as was well illustrated in Fig. 2. All the four lymph nodes with *Wuchereria bancrofti* granuloma contained adult worms in the dilated lymph channels. The finding of *Onchocerca volvulus* granuloma in inguinal lymph node composed of dense whorled fibrous tissue with areas of calcification is not surprising because onchocerciasis is endemic in this part of Nigeria. This observation is supported by the report of Edungbola (1982) which demonstrates that 63% of 4436 subjects examined in Kwara State of Nigeria have microfilariae of *Onchocerca volvulus* in their skin snips and that 51% of them have onchocercal skin nodules.

Of the 142 cases of lymph node metastatic cancer and malignant lymphoma, 70 were malignant lymphoma. Unlike metastatic tumours, malignant lymphoma affects a relatively young population of patients. Forty-seven of the 72 metastatic cancers had known primary sources while the remaining 25 cases were of indeterminate origin. The frequency of the metastatic lesions to the superficial lymph nodes was the neck, axilla and groin in that order. In line with previous studies (Jesse et al., 1973; Krementz et al., 1977; Smith et al., 1967), the cervical lesions with determined origin were from the breast, stomach, pancreas, salivary gland, thyroid and lung while the most frequent metastatic lesions in the axilla was breast carcinoma. The observation that 10 of the 19 metastatic tumours in the groin were malignant melanoma appears to confirm the reports of Oluwasanmi et al. (1969) from Nigeria and Krementz et al. (1976) from America which indicate that there is a higher incidence of melanoma of the lower extremities in black than white patients. This study also demonstrates that the most common location of the lymph node metastases of undetermined origin was the neck which is in keeping with earlier reports (Krementz et al., 1977; Smith et al., 1967).

It must be admitted that this report does not give a true incidence of the causes of peripheral lymphadenopathy in the tropics. A prospective study which biopsies all enlarged superficial lymph nodes can only give an unbiased true incidence of the lesion. A retrospective study like the present one may have a selection bias because the primary physician may eliminate some cases prior to referring to a surgeon who in turn decides the need to biopsy an enlarged lymph node. We, however, believe that in spite of this bias, this report offers all clinicians in the tropics a guide to the causes of enlarged peripheral lymph node.

- Adeiga A., Ahmed A.: Prevalence of toxoplasma antibodies in pregnant women in Lagos State. *West. Afr. J. Med.* 2, 92–95 (1983).
- Attiyeh F. F., Jensen M., Huvos A. G., Fracchla A.: Axillary micrometastasis and macrometastasis in carcinoma of the breast. *Obstet. Gynec.* 144, 839–842 (1977).
- Berg W. J., Huvos A. G., Axtell L. M., Rubbins G. F.: A new sign of favourable prognosis in mammary cancer: hyperplastic reactive nodes in the apex of the axilla. *Ann. Surg.* 177, 8–12 (1973).
- Dorfman R. F., Remington J. S.: Value of lymph node biopsy in the diagnosis of acute acquired toxoplasmosis. *New Engl. J. Med.* 289, 878–881 (1973).
- Edungbola L. D.: Prevalence of onchocerciasis in Ile-Ire District (Ifelodun), Kwara State, Nigeria. *Trop. geogr. Med.* 34, 231–239 (1982).
- Farer L. S., Lowell A. M., Meador M. P.: Extrapulmonary tuberculosis in the United States. *Amer. J. Epidemiol.* 109, 205–217 (1979).
- Fraser H. S.: Peripheral tuberculous lymphadenitis. *Brit. J. Dis. Chest* 59, 164–172 (1965).
- Jesse R. H., Perez C. A., Fletcher G. H.: Cervical lymph node metastasis; unknown primary cancer. *Cancer (Philad.)* 31, 854–859 (1973).
- Kremenz E. T., Cerise E. J., Ciaravella J. M., Morgan L. Y.: Metastases of undetermined source. *Cancer N.Y.* 27, 289–300 (1977).
- Kremenz E. T., Sutherland C. M., Carter R. D., Ryan R. F.: Malignant melanoma in the American Black. *Ann. Surg.* 183, 533–542 (1976).
- Oluwasanmi S. O., Williams A. O., Alli A. F.: Superficial cancer in Nigeria. *Brit. J. Cancer* 23, 714–728 (1969).
- Raz I., Haas H.: Tuberculous axillary lymphadenitis: an unusual presentation. *Tubercle (Edinb.)* 64, 41–42 (1983).
- Smith P. E., Kremenz E. T., Chapman W.: Metastatic cancer without a detectable primary site. *Amer. J. Surg.* 113, 633–637 (1967).
- Stansfeld A. O.: The histological diagnosis of toxoplasmic lymphadenitis. *J. clin. Path.* 14, 565–573 (1961).