

Pentastomiasis : case report of an acute abdominal emergency

Autor(en): **Herzog, U. / Marty, P. / Zak, F.**

Objektyp: **Article**

Zeitschrift: **Acta Tropica**

Band (Jahr): **42 (1985)**

Heft 3

PDF erstellt am: **22.07.2024**

Persistenter Link: <https://doi.org/10.5169/seals-313477>

Nutzungsbedingungen

Die ETH-Bibliothek ist Anbieterin der digitalisierten Zeitschriften. Sie besitzt keine Urheberrechte an den Inhalten der Zeitschriften. Die Rechte liegen in der Regel bei den Herausgebern.

Die auf der Plattform e-periodica veröffentlichten Dokumente stehen für nicht-kommerzielle Zwecke in Lehre und Forschung sowie für die private Nutzung frei zur Verfügung. Einzelne Dateien oder Ausdrucke aus diesem Angebot können zusammen mit diesen Nutzungsbedingungen und den korrekten Herkunftsbezeichnungen weitergegeben werden.

Das Veröffentlichen von Bildern in Print- und Online-Publikationen ist nur mit vorheriger Genehmigung der Rechteinhaber erlaubt. Die systematische Speicherung von Teilen des elektronischen Angebots auf anderen Servern bedarf ebenfalls des schriftlichen Einverständnisses der Rechteinhaber.

Haftungsausschluss

Alle Angaben erfolgen ohne Gewähr für Vollständigkeit oder Richtigkeit. Es wird keine Haftung übernommen für Schäden durch die Verwendung von Informationen aus diesem Online-Angebot oder durch das Fehlen von Informationen. Dies gilt auch für Inhalte Dritter, die über dieses Angebot zugänglich sind.

¹ St. Clara-Spital, Chirurgie, Basel, Switzerland.

² Faculté de Médecine, Nice, France

³ Department of Toxicology, Ciba-Geigy Ltd., Basel, Switzerland

Pentastomiasis: case report of an acute abdominal emergency

U. HERZOG¹, P. MARTY², F. ZAK³

Summary

A 34-year-old native woman presented as an acute abdominal emergency at the Surgery Department, Missionary Hospital "Ad Lucem" in Banka-Bafang, Cameroon. She complained of colicky, epigastric abdominal pain, nausea, vomiting, constipation, and retention of flatus. At laparotomy, numerous small cystic nodules (3–8 mm in diameter) were noted in the mesentery and under the intestinal and parietal peritoneum. Histological examination of two of them revealed slightly enlarged mesenteric lymph nodes containing several parasitic pseudocysts. The parasites were diagnosed as well-preserved, encysted, *Armillifer armillatus* nymphs. Neither degenerative nor inflammatory granulomatous reactions were observed in the adjacent tissue. Two and a half years later, a similar attack of acute abdominal symptoms recurred. A radiological examination revealed several C-shaped or circular, dense opacities characteristic of calcified pentastomid nymphs. At laparotomy, local findings similar to those at the previous surgical examination were noted. Additionally, a few firm, whitish, calcified nodules were found in the mesentery and under the fibrous capsule of the liver.

Key words: pentastomiasis; nymphal stage of *Armillifer armillatus* infection; acute abdominal emergency; peritoneum; mesenteric lymphnodes; histopathology; X-ray examination.

Introduction

Pentastomiasis is an infection caused by a member of the phylum Pentastomida. The name pentastomid was given not through the presence of 5 mounths, but because of the two pairs of anterior hooks, and a mouth which

Correspondence: Dr. U. Herzog, St. Clara-Spital, Chirurgie, CH-4058 Basel, Switzerland – PD Dr. F. Zak, Department of Toxicology, Ciba-Geigy Ltd., CH-4002 Basel, Switzerland

gives the appearance of having 5 openings. The Pentastomida constitute an old and highly aberrant group of parasites. The taxonomic rank of these has always been controversial to zoologists (Sambon, 1922; Faust, 1927; Fain, 1966, 1973; Fain and Salvo, 1966; Self et al., 1972; Meyers et al., 1976; Dönges, 1980). In spite of some affinities with both the arthropods and the annelids (Sambon, 1922; Self et al., 1972; Dönges, 1980), they cannot be precisely attached to any existing group of animals; classification as an independent phylum (Pentastomida) has, therefore, been proposed (Fain, 1966; 1973; Meyers et al., 1976).

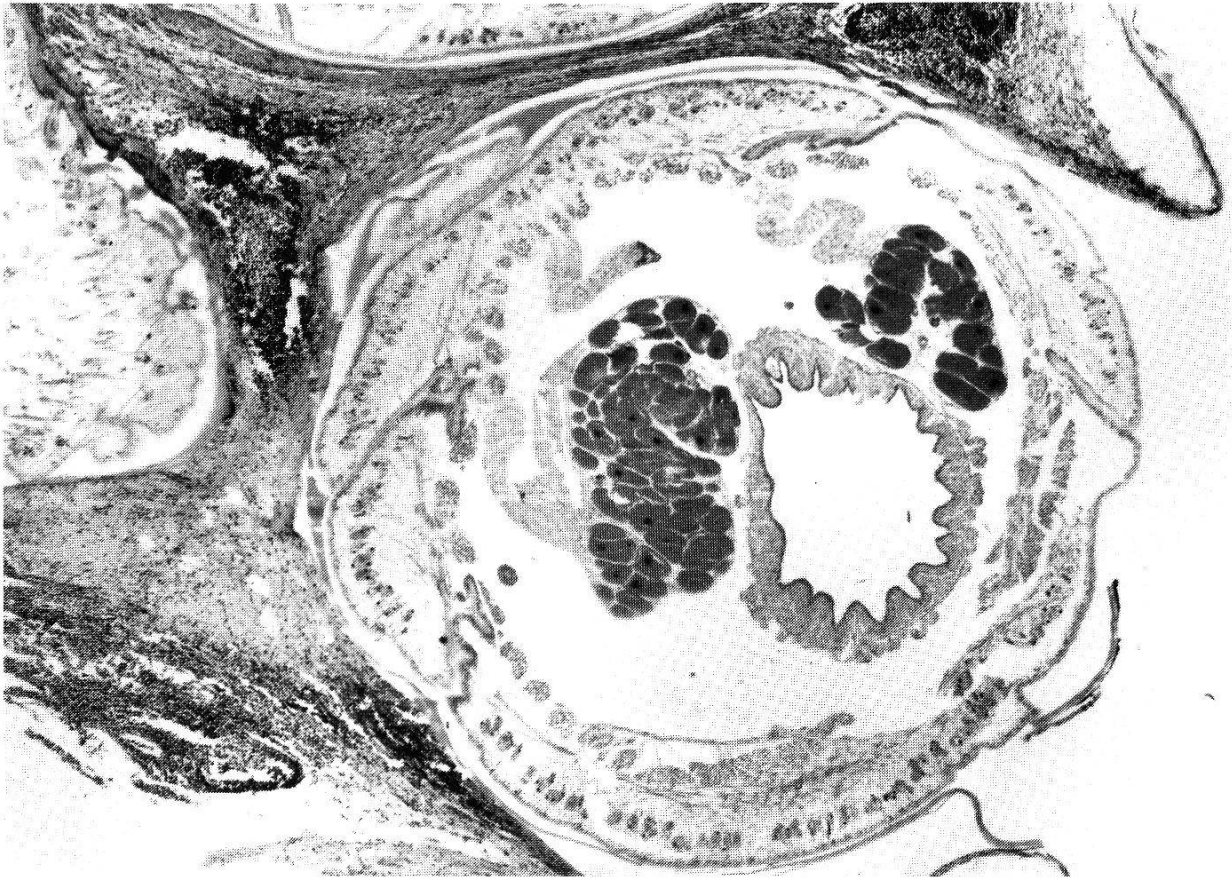Within this group there are two families of medical importance to man: porocephalidae and linguatulidae. The adult porocephalidae inhabit the respiratory tract of some reptiles (such as pythons and vipers of the genus *bitis*), and adult linguatulidae the nasal passages of carnivorous mammals (such as dogs, wolves, foxes, etc.). Embryonated eggs, discharged in the faeces or in the secretion from the respiratory tract, lodge on vegetation or contaminate water. Many vertebrates, including primates (Reardon and Rininger, 1968; Cosgrove et al., 1970; Self, 1972) and man, may serve as intermediate hosts (Sambon, 1922; Fain and Mortelmans, 1960; Bosson et al., 1971; Meyers et al., 1976).

Parasitism of man by adult pentastomids is very exceptional and it has been observed only with *Linguatula serrata* infection (Galli-Valerio, 1921; Fain, 1973; Meyers et al., 1976). Nymphal pentastomiasis in man, however, has been reported on numerous occasions and in various parts of the world; it is generally accepted that the pentastomid nymphs do little, if any, harm, usually being found incidentally at radiological investigations (Van Wymeersch and Wanson, 1954; Lindner, 1965; Rail, 1967; Smith et al., 1975; Tiendrebeogo et al., 1982), surgery (Manuwa, 1946; Symmers and Valteris, 1950; Symmers, 1957; Dönges, 1966; Buchanan, 1967; Discamps and Albert, 1974; Bygbjerg and Rask, 1978), or autopsies (Waldow, 1908; Seifert, 1910; Schaefer, 1912; Löhlein, 1912; Macfie and Johnston, 1913; Mouchet, 1913, 1914; Sagredo, 1924; Riding, 1926; Sonobe, 1927; Porter, 1928; Symmers and Valteris, 1950; Tobie et al., 1957; Prathap et al., 1969; Smith et al., 1975); however, under some circumstances they may cause serious damage and produce remarkable clinical symptoms, because of either their location (Fornara, 1924; Cannon, 1942; Symmers, 1957) or the large numbers involved (Cannon, 1942; Fain, 1960; Buchanan, 1967; Tiendrebeogo et al., 1982); there are even several clinical references to cases which associate pentastomid infestation with death (Raebiger, 1910; Fornara, 1924; Cannon, 1942; Cagnard et al., 1979; Tiendrebeogo et al., 1982).

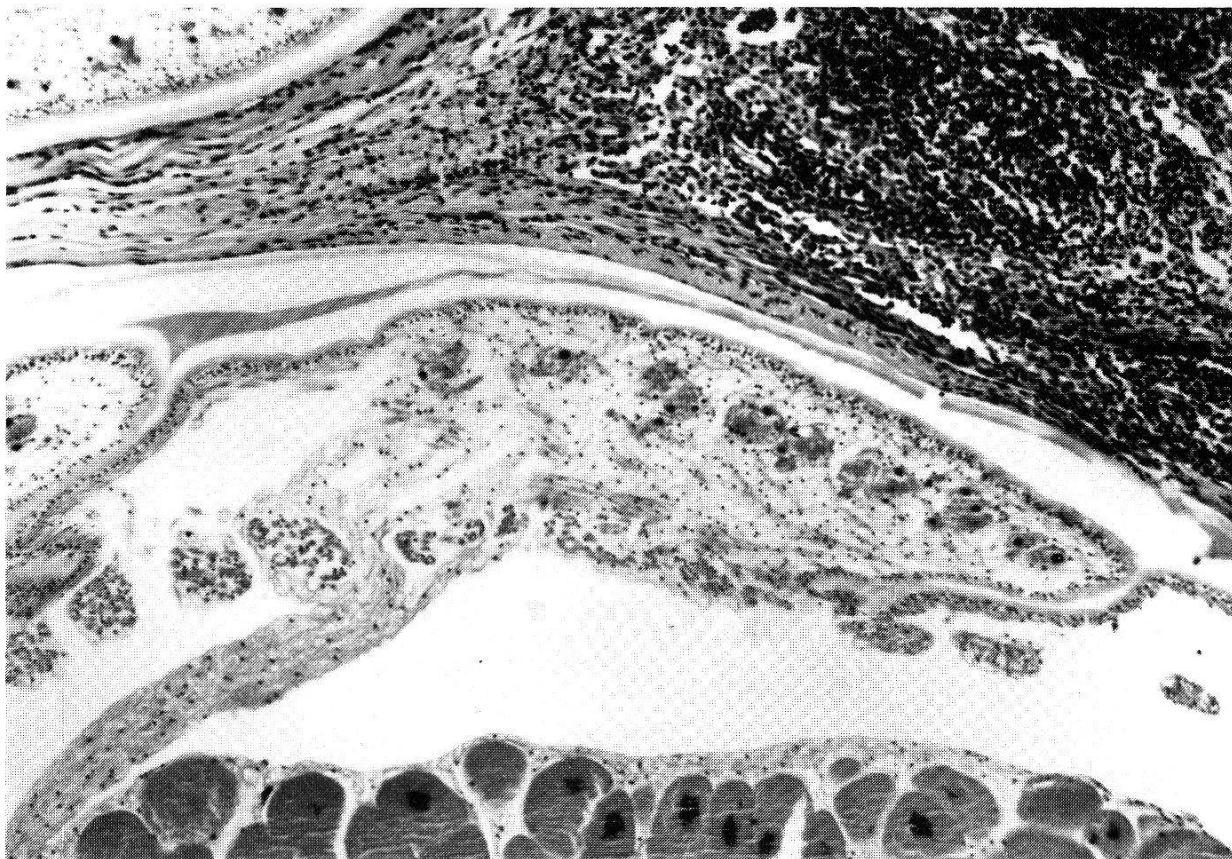
In this paper, we refer to a case of massive infestation with *Armillifer armillatus* nymphs presenting as an acute abdominal emergency.

Fig. 1. Mesenteric lymph node with encysted nymph of *Armillifer armillatus*. Note prominent acidophilic glands, intestinal tract and smooth cuticle. Haematoxylin-eosin stain, magn. 21 ×.

Fig. 2. Encysted nymph of *Armillifer armillatus* showing smooth cuticle, subcuticular glands and striated muscle fibres. Haematoxylin-eosin stain, magn. 84 ×.



1



2

Case report

A married woman, 34 years old, a native of Penja/Moungo in Cameroon, was admitted in August 1980 as an acute abdominal emergency to the missionary hospital "ad Lucem" in Banka-Bafang, Cameroon. She complained of acute, colicky epigastric pain, nausea, vomiting, constipation, and retention of flatus of 2-day duration. She had suffered from abdominal discomfort for several years and had been treated, without obvious success, by various antacid drugs, and Cimetidin. However, radiological investigation of the gastrointestinal tract had never been performed.

Haematological examination gave the following results: haemoglobin 11.29%, leucocytes $8600/\text{mm}^3$, of which neutrophil polymorphonuclears accounted for 48%, eosinophils 5%, monocytes 8%, and lymphocytes 39%; ESR (erythrocyte sedimentation rate) was 23 and 47 mm, respectively. The urine was unremarkable, and no parasites were discovered in the faeces. Although no definite pathological changes were observed at the plain roentgenogram, exploratory laparotomy was performed because of deterioration in the clinical symptoms. After opening the abdominal cavity, numerous disseminated, cystic nodules (3–8 mm in diameter) were found in the mesentery and under the visceral and parietal peritoneum. No pathological changes were noted on the stomach, duodenum, and liver. A biopsy from two of these cystic lesions was taken.

The patient showed a smooth, uneventful, postoperative course. She was treated with Thiabendazole (Mintezol, 2×2 tabl. = 2 g daily). Four weeks after surgery the abdominal pain and symptoms had disappeared. At the control examination in April 1982, the patient was in good general condition and without subjective symptoms. In September 1983, however, she was again admitted to the hospital with acute abdominal symptoms similar to those in August 1980. Laboratory examination revealed haemoglobin 11.8%, haematocrit 48%, leucocytes $5200/\text{mm}^3$, of which neutrophil polymorphonuclears accounted for 63%, eosinophils 4%, and lymphocytes 33%; ESR was 23 and 52 mm respectively, SGOT 18, SGPT 12, and alkaline phosphatase 63 IU/l. Simple X-ray examination showed a few C-shaped or circular dense opacities in the abdominal region. At the (second-look) surgical operation, numerous small, disseminated cysts and whitish nodules were again noted in the abdominal peritoneum, especially in the mesentery (Fig. 3); some of the nodules were firm and calcified, some contained immobile nymphs, while from others free-moving nymphs (Fig. 4) could be released. Several disseminated cysts and nodules were also found under Glisson's capsule (of the liver), but no evidence of liver neoplasia was noted. One of us (P. M.) and Prof. Doucet from the Medical Faculty University of Nice, France, have examined the nymphs, however fixed in formalin; and according to the morphology and the number of annulations (16–22 dorsal and 18–24 ventral) have diagnosed them as nymphs of *Armillifer armillatus*.

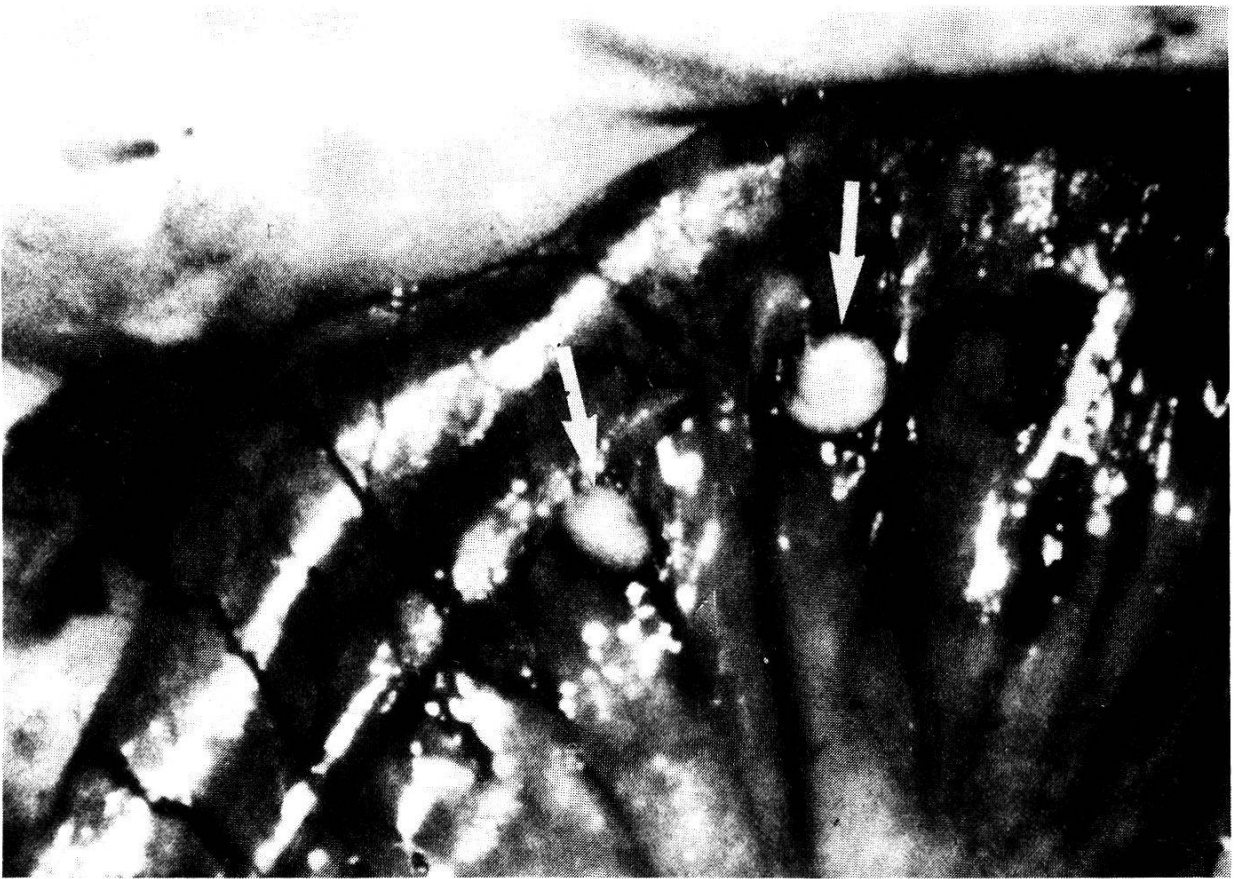The postoperative course was again uncomplicated; therapy with Thiabendazole (Mintezol, 2×2 tabl. = 2 g daily) was suggested.

Histopathological examination

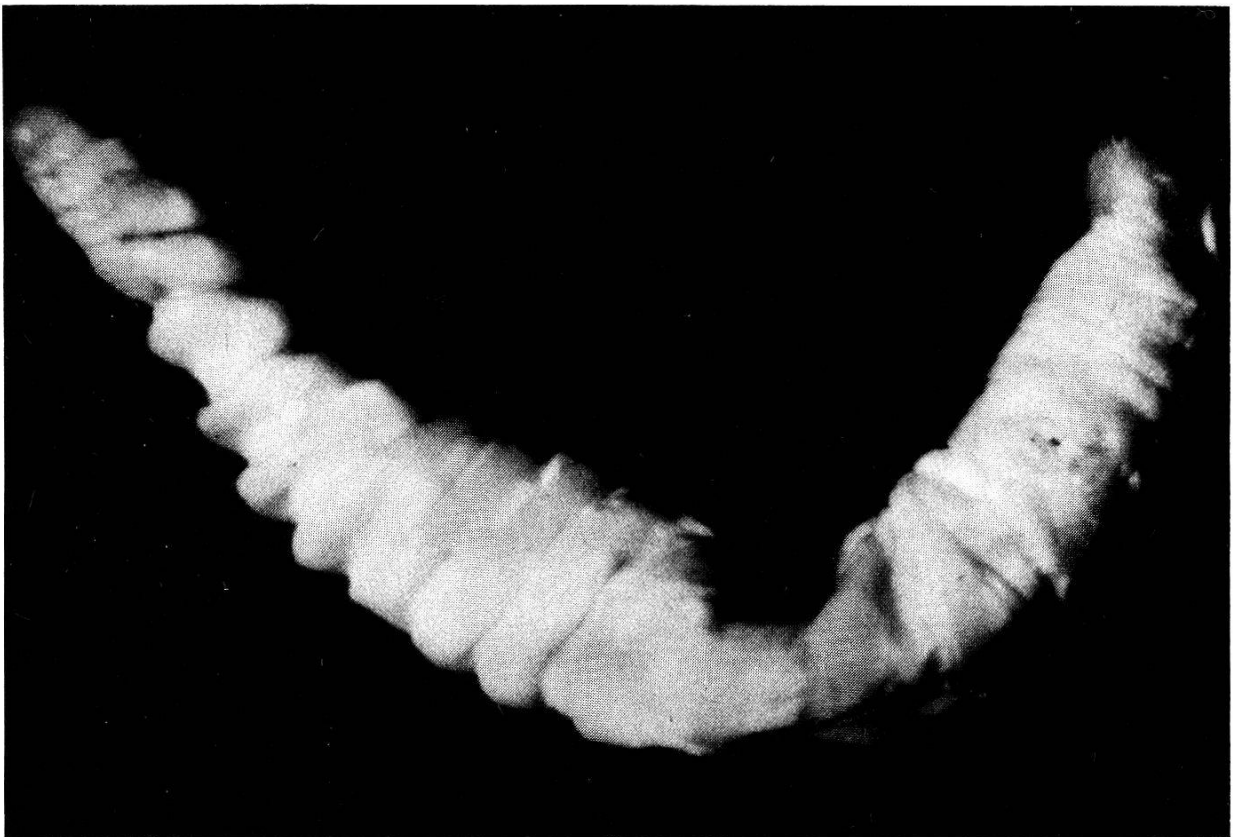
The excised tissue samples, after fixation in formalin solution, measured 10 by 6 mm and 15 by 8 mm, respectively; small cysts were apparent on the cut surface. At microscopical examination, both samples were seen to be made up of slightly enlarged lymph nodes. Within these nodes there were several, well-preserved, encysted nymphs of *Armillifer armillatus* showing the typical, prominent acidophilic glands and intestinal tract (Fig. 1); the chitinous cuticle was smooth without spines, 6 to 10 microns thick, and contained sclerozed openings; subcuticular glands and striated muscle fibres were apparent beneath the cuticle (Fig. 2). Both the parasites and the cyst linings gave a positive periodic-acid Schiff reaction. Normal lymph node structures were separated from the encysted nymphs by a thin, delicate fibrous capsule. Neither degenerative nor granulomatous inflammatory reactions were noted in the adjacent lymph node tissue.

Fig. 3. Small intestine (during surgery) with two small cystic nodules (arrows) in the mesentery.

Fig. 4. *Armillifer armillatus* nymph removed from the cyst showing typical annulations.



3



4

Discussion

Nymphal pentastomiasis in man has been reported from Europe, Africa, Asia, and the Americas; five species (*Linguatula serrata*, *Armillifer (A.) armillatus*, *A. moniliformis*, *A. grandis*, and *Porocephalus crotali*) are known to be possible parasites of man (Sambon, 1922; Cannon, 1942; Fain, 1960). Adults and nymphs of *Linguatula serrata* are parasitic in numerous wild and domestic animals in all parts of the world (Sambon, 1922) – in some areas of Europe about 10% of the dogs harbour this organism. Human cases of *L. serrata* infestation have been published from Europe (Galli-Valerio, 1921; Sagredo, 1924; Symmers and Valteris, 1950; Symmers, 1957; Mumcuoglu and Ruffi, 1981), from North America (Tobie et al., 1957; Hunter and Higgins, 1960; Deweese et al., 1962; Rendtorff et al., 1962; Mendeloff, 1965; Ali-Khan and Bowmer, 1972), from Morocco (Le Corroller and Pierre, 1959), as well as from India (Roy and Ganguly, 1940), and China (Faust, 1927); however, it must be assumed that the occurrence of linguatuliasis is much more widespread than published reports indicate. Human pentastomiasis due to Armilliferidae is relatively frequent in Tropical Africa – there are reports published early in the century (Waldow, 1908; Löhlein, 1912; Schaefer, 1912; Macfie and Johnston, 1913; Mouchet, 1913, 1914; Riding 1926; Cannon, 1942; Manuwa, 1946), as well as during the last two decades (Dönges, 1966; Fain and Salvo, 1966; Fain, 1966, 1975; Discamps and Albert, 1974; Cagnard et al., 1979; Nozais et al., 1982; Tiendrebeogo et al., 1982). A good historical review of pentastomid infestation in man, with numerous earlier references, is found in the papers of Cannon (1942) and Fain (1960; 1966). Human nymphal parasitosis with *A. moniliformis* has been reported from South-East Asia (Rail, 1967; Prathap et al., 1969) and with *Porocephalus crotali* from South America (Sambon, 1922).

As already mentioned, man is usually highly tolerant to infections with pentastomids – most are asymptomatic and only discovered incidentally. However, human nymphal pentastomiasis has also been associated with a variety of conditions including ascites and pericardial effusion (Wilson, 1915), obstructive jaundice (Monziols et al., 1920), lymphatic obstruction (Pons and Noc, 1922), pneumothorax (Cagnard et al., 1979), palpable intradermal nodules (Bygbjerg and Rask, 1978; Cagnard et al., 1979), painful urination (Symmers, 1957), and marked cachexia (Cagnard et al., 1979). Ocular involvement, with associated symptoms, has been described in infestation by nymphs of *Linguatula serrata* (Hunter and Higgins, 1960; Deweese et al., 1962; Rendtorff et al., 1962), *Armillifer armillatus* (Reid and Ellis-Jones, 1963; Fontanel et al., 1972), as well as with *Armillifer grandis* (Cagnard et al., 1979).

Symptoms of acute abdominal emergency with severe abdominal pain, vomiting, absolute constipation, and a markedly distended and tender (but not rigid) abdomen, were also associated with severe *Armillifer armillatus* infection in a Nigerian (Yoruba) male, aged 28 (Buchanan, 1967). A case of perforation

of the ileum by a pentastomid nymph has been recorded by Vande Voorde (1956), and discussed by Buchanan (1967). Bouckaert and Fain (1959) described a fatal case of an acute intestinal obstruction of the colon produced by nymph of *Armillifer armillatus*. Apart from these three cases, we could find no other reference to pentastomiasis as a cause of an acute abdominal emergency.

A particular problem is the relation between the developing nymphs or adults of *Linguatula serrata* and the Halzoun (Lebanon) or Marrara (Sudan) syndrome, a well-recognized but etiologically indefinite disease in man. This syndrome is associated with eating raw liver, lungs, and the stomach of goats or sheep; dyspnoea, dysphagia, disphony, frontal headache, and acute attacks of coughing and sneezing are common symptoms; severe acute rhinopharyngitis with oedematous congestion of the buccopharyngeal mucosa, tonsils, larynx, nasal passages, conjunctiva, and lips are the major pathological findings.

Several times, free nymphs of *Linguatula serrata* or adult parasites were recovered from the nasopharynx of patients with this syndrome (Papadakis and Hourmouziadis, 1958; Le Corroller and Pierre, 1959; Khalil and Schacher, 1965; Schacher et al., 1969). Khalil and Schacher (1965) showed that orally administered *L. serrata* nymphs became attached to the pharynx, larynx, trachea, or bronchi of various laboratory animals, evoking symptoms similar to those of Halzoun in man – nymphs administered by stomach tube to rabbits and dogs could be recovered from the pharynx, mouth, and nasal cavities within 2 hours.

The possible relation between pentastomiasis and cancer has also been discussed (Fain and Mortelmans, 1960; Smith et al., 1975; Bygbjerg and Rask, 1978). In our opinion, the recorded cases of pentastomiasis in association with cancer of the colon (Bygbjerg and Rask, 1978), polyposis of the jejunum and Hodgkin's disease with *Armillifer armillatus* infestation (Smith et al., 1975), acute leukaemia with *Linguatula serrata* infestation (Tobie et al., 1957), or that of fibrosarcoma of the nasal cavity invaded by an adult *Linguatula serrata* (Galli-Valerio, 1921), are more likely to be fortuitous coincidences than causally related events.

In man, the pentastomid infestation generally results from the consumption of water or food (crude vegetable) contaminated by faeces, or by the naso-bronchial secretions of infected snakes or carnivores, more rarely by eating raw or inadequately cooked snake or lizard, or the flesh of another definite host. In our case, the patient, as a mother of twins, was strictly forbidden to eat snake meat; therefore, repeated infestation from contaminated water or vegetables was probably the source of the severe infection.

Identification of pentastomids, from biopsy specimens or necropsy material, can be ascertained either by detailed morphological examination of viable and/or well-preserved nymphs (Sambon, 1922; Sagredo, 1924; Joyeux and Prade, 1945; Fain, 1960; Hunter and Higgins, 1960; Reid and Ellis-Jones, 1963; Dönges, 1966; Fain and Salvo, 1966; Schacher et al., 1969; Cagnard et al.,

1979), or by histological examination of the parasites in tissue sections (Symmers and Valteris, 1950; Symmers, 1957; Tobie et al., 1957; Doucet, 1965; Mendeloff, 1965; Chitwood and Lichtenfels, 1972; Self, 1972; Ali-Khan and Bowmer, 1972; Discamps and Albert, 1974; Smith et al., 1975). Encysted viable nymphs usually cause little or no reaction in the host tissue even at a high level of infestation; those of *Armillifer armillatus* can be identified by prominent acidophilic glands; the chitinous cuticle, which contains sclerosed openings, is smooth in *A. armillatus* or contains spines in *Linguatula serrata*. Subcuticular glands and striated muscle fibres lie beneath the cuticle. There are prominent hooks in the anterior end of the larva.

Cysticerci, spargana, and tissue-inhabiting arthropods, may sometimes be confused with pentastomids. Cysticerci and spargana can be distinguished by their lack of a digestive tract, reproductive organs, striated muscle, and sclerosed openings in the cuticle. Arthropods differ from pentastomids by the presence of numerous tracheal tracts (Meyers et al., 1976). Inflammation in pentastomiasis always involves dead nymphs: they release large amounts of foreign protein into the host tissues as they disintegrate, and an inflammatory response ensues; occasionally there may be abscess formation (Self, 1972), or massive infiltration by eosinophilic leucocytes may be noted (Symmers, 1957). The dead nymphs may eventually calcify, or their disintegrated fragments may elicit a marked granulomatous reaction with the occurrence of foreign-body giant cells. Old granulomas may only contain fragments of cuticle which are frequently difficult to identify (Symmers and Valteris, 1950; Mendeloff, 1965; Ali-Khan and Bowmer, 1972).

Histopathological findings, similar to those in human nymphal pentastomiasis, were noted in animals infected either spontaneously (Cosgrove et al., 1970) or experimentally (Esslinger, 1962; Self, 1972; Self et al., 1972).

Serological methods of diagnosis are of great value in all fields of parasitology, and pentastomiasis is no exception; they have certain advantages over conventional parasitological methods and histopathology in that they avoid the need for biopsy. Various techniques and tests for the detection of anti-*Armillifer* antibodies such as indirect immunofluorescence, gel diffusion test, or immunoelectrophoresis were developed and used in recent years (Ranque et al., 1972; Amy, 1973; Amy et al., 1974; Discamps and Albert, 1974; Nozais et al., 1982; Tiendrebeogo et al., 1982). The main difficulty, for the time being is in the preparation of antigens of good quality in sufficient quantity.

Acknowledgments

Our sincere thanks are due to Prof. J. Doucet, Faculté de Médecine, Nice (France), and Prof. B. Hörning, Veterinary Faculty, University of Bern, for encouragement and valuable advice, to Dr. Ch. Thüer, Kantonsspital Winterthur, for collegial support, to Mr. K. Traber for photographic technical assistance, and to Miss R. Fiechter for typing the manuscript of this paper and for her reliable secretarial assistance.

- Ali-Khan Z., Bowmer E. J.: Pentastomiasis in Western Canada. *Amer. J. trop. Med. Hyg.* 21, 58–61 (1972).
- Amy D.: La pentastomose à *Armillifer armillatus*. Etude biologique, immunologique et radiologique. Thèse, Faculté de Médecine, Marseille 1973.
- Amy D., Ranque Ph., Discamps G., Rougemont A., Quilici M.: La pentastomose humaine. *Méd. trop.* 34, 273–278 (1974).
- Bosson P. A., McCully R. M., Kruger S. P., Van Nierk J. W., Young E., De Vos V., Keep M. E., Ebedes H.: Krankheiten beim südafrikanischen Wild. *Vet.-med. Nachr.* 2, 305–332 (1971).
- Bouckaert L., Fain A.: Een geval van nymphale porocephalose met dolelijk verloop. *Ann. Soc. belge Méd. trop.* 39, 793–797 (1959).
- Buchanan G.: Surgical aspects of porocephalosis. *Trans. roy. Soc. trop. Med. Hyg.* 61, 746–747 (1967).
- Bygbjerg I. C., Rask M. P.: Pentastomiasis and cancer of the colon. *Trans. roy Soc. trop. Med. Hyg.* 72, 54–55 (1978).
- Cagnard V., Nicolas-Randegger J., Dago Akribi A., Rain B., Nozais J. P., Essoh Nomel P., Etter M., Doucet J., Assale N'Diri G.: Pentastomose généralisée et mortelle à *Armillifer grandis* (Hett, 1915). *Bull. Soc. Path. exot.* 72, 345–352 (1979).
- Cannon D. A.: Linguatulid infestation of man. *Ann trop. Med.* 36, 160–167 (1942).
- Chitwood M., Lichtenfels J. R.: Identification of parasitic metazoa in tissue sections. *Exp. Parasit.* 32, 407–519 (1972).
- Cosgrove G. E., Nelson B. M., Self J. T.: The pathology of pentastomid infection in primates. *Lab. Animal Care* 20, 354–360 (1970).
- Deweese M. W., Murrah W. F., Caruthers S. B.: Case report of a tongue worm (*Linguatula serrata*) in the anterior chamber. *Arch. Ophthalm.* 68, 587–589 (1962).
- Discamps G., Albert J. P.: La pentastomose (à propos de 4 cas récents). *Méd. trop.* 34, 279–285 (1974).
- Dönges J.: Parasitäre Abdominalzysten bei Nigerianern. *Z. Tropenmed. Parasit.* 17, 252–256 (1966).
- Dönges J.: Parasitologie. G. Thieme Verlag, Stuttgart 1980.
- Doucet J.: Contribution à l'étude anatomique, histologique et histochimique des Pentastomes. *Mém. Orstom Paris* 14, 1–15 (1965).
- Esslinger J. H.: Hepatic lesions in rats infected with *Porocephalus crotali* (Pentastomida). *J. Parasit.* 48, 631–638 (1962).
- Fain A.: La pentastomose chez l'homme. *Bull. Acad. roy. Méd. Belg.* 25, 516–532 (1960).
- Fain A.: Pentastomida of snakes – their parasitological role in man and animals. *Mem. Inst. Butantan* 33, 167–174 (1966).
- Fain A.: Pentastomids. In: *Parasitic laboratory animals*, ed. by Flynn, p. 493–503. Iowa State Univ. Press, Iowa 1973.
- Fain A.: The pentastomida parasitic in man. *Ann. Soc. belge Méd. trop.* 55, 59–64 (1975).
- Fain A., Mortelmans J.: Observations sur le cycle évolutif de *Sambonia Lohrmanni* chez le Varan (preuve d'un développement direct chez les Pentastomida). *Bull. Acad. Sci. Belg. 5e sér.* 46, 518–531 (1960).
- Fain A., Salvo G.: Pentastomose humaine produite par des nymphes d'*Armillifer grandis* (Hett) en République démocratique du Congo. *Ann. Soc. belge Méd. trop.* 46, 675–682 (1966).
- Faust E. C.: Linguatulid (order Acarina) from man and other hosts in China. *Amer. J. trop. Med.* 7, 311–325 (1927).
- Fontanel A., Doucet J., Loubière R.: Pentastomose conjonctivale. *Presse méd.* 80, 3123–3124 (1972).
- Fornara L.: Note sur un cas de localisation sous-arachnoïdienne d'une larve de Porocephale. *Ann. Soc. belge Méd. trop.* 3, 233–236 (1924).
- Galli-Valerio B.: Parasitologische Untersuchungen und Beiträge zur parasitologischen Technik. *Zbl. Bakt.* 86, 346–352 (1921).

- Hunter W. S., Higgins R. P.: An unusual case of human porocephaliasis. *J. Parasit.* 46, 68 (1960).
- Joyeux Ch., Prade J.: Une linguatule évacuée dans les selles. *Marseille méd.* 82, 341–346 (1945).
- Khalil G. M., Schacher J. F.: *Linguatula serrata* in relation to Halzoun and the Marrara syndrome. *Amer. J. trop. Med. Hyg.* 14, 736–746 (1965).
- Le Corroller Y., Pierre J. L.: Sur un cas de linguatulose humaine au Maroc. *Bull. Soc. Path. exot.* 52, 730–733 (1959).
- Lindner R. R.: Retrospective X-ray survey for porocephalosis. *J. trop. Med. Hyg.* 68, 155–156 (1965).
- Löhlein M.: Beiträge zur Pathologie der Eingeborenen von Kamerun. *Arch. Schiffs- u. Tropenhyg.* 16, 637–746 (1912).
- Macfie J. W. S., Johnston J. E. L.: A note on five cases of porocephaliasis in man from Southern Nigeria. *Lancet* 1913/II, 1387–1389.
- Manuwa S. L. A.: Porocephalosis. *Trans. roy. Soc. trop. Med. Hyg.* 40, 507–508 (1946).
- Mendeloff J.: Healed granulomas of the liver due to tongue worm infection. *Amer. J. clin. Path.* 43, 433–437 (1965).
- Meyers W. M., Naefie R. C., Connor D. H.: Pentostomiasis. In: *Pathology of tropical and extraordinary diseases*, ed. by C. H. Binford and D. H. Connor, p. 546–550. Armed Forces Institute of Pathology, Washington D. C. 1976.
- Monziols, Collignon, Roy J.: Un cas d'ictère grave suivi de mort et causé chez un Sénégalais par le *Porocephalus armillatus* Wyman. *C.R. Soc. Biol. (Paris)* 83, 28–29 (1920).
- Mouchet R.: Notes anatomiques et médicales sur la pathologie du Moyen Congo. *Arch. Schiffs- und Tropenhyg.* 17, 657–669 (1913).
- Mouchet R.: Note sur *Porocephalus moniliformis*. *Bull. Soc. Path. exot.* 7, 497–501 (1914).
- Mumcuoglu Y., Ruffi Th.: Pentastomida/Zungenwürmer. *Schweiz. Rundschau Med. (Praxis)* 70, 1923–1926 (1981).
- Nozais J. P., Cagnard V., Doucet J.: La pentastomose. Enquête sérologique chez 193 Ivoiriens. *Méd. trop.* 42, 497–499 (1982).
- Papadakis A. M., Hourmouziadis A. N.: Human infestation with *Linguatula serrata*. *Trans. roy. Soc. trop. Med. Hyg.* 52, 454–455 (1958).
- Pons R., Noc F.: Porocéphaliase ganglionnaire et lymphadéine tuberculeuse à évolution rapide chez un tirailleur sénégalais. *Bull. Soc. Path. exot.* 15, 951 (1922). ref. Cannon (1942).
- Porter A.: Note on a porocephalid found in a Shangaan in South Africa. *S. Afr. J. med. Sci.* 25, 359–363 (1928).
- Prathap K., Lau K. S., Bolton J. M.: Pentastomiasis: a common finding at autopsy among malaysian aborigines. *Amer. J. trop. Med. Hyg.* 18, 20–27 (1969).
- Raebiger A.: Geisteskrankheit bei einem Kamerunneger, bedingt durch Porocephaliasis. *Arch. Schiffs- u. Tropenhyg.* 14, 170–174 (1910).
- Rail G. A.: Porocephaliasis: a description of two cases in Sabah. *Trans. roy. Soc. trop. Med. Hyg.* 61, 715–717 (1967).
- Ranque Ph., Mattei X., Quilici M.: Première étude concernant les anticorps fluorescents et précipitants en gélose anti-*Armillifer armillatus* Wyman. *C.R. Acad. Sci. (Paris)* 275, 437–439 (1972).
- Reardon L. V., Rininger B. F.: A survey of parasites in laboratory primates. *Lab. Animal Care* 18, 577–580 (1968).
- Reid A. M., Ellis-Jones D. W.: *Porocephalus armillatus* larvae presenting in the eye. *Brit. J. Ophthalm.* 47, 169–172 (1963).
- Rendtorff R. C., Deweese M. W., Murrah W.: The occurrence of *Linguatula serrata*, a Pentastomid, within the human eye. *Amer. J. trop. Med. Hyg.* 11, 762–764 (1962).
- Riding D.: A case of porocephalosis. *Ann. trop. Med. Parasit.* 20, 143–144 (1926).
- Roy D. N., Ganguly S. K.: Linguatulid infection in man. *Indian med. Gaz.* 75, 478 (1940).
- Sagredo N.: *Linguatula rhinaria* Larve (*Pentastoma denticulatum*) in den Lungen des Menschen. *Virchows Arch. path. Anat.* 251, 608–615 (1924).
- Sambon L. W.: A synopsis of the family Linguatulidae. *J. trop. Med. Hyg.* 25, 188–206 and 391–428 (1922).

- Schacher J. F., Saab S., Germanos R., Boustany N.: The aetiology of Halzoun in Lebanon: recovery of *Linguatula serrata* nymphs from two patients. *Trans. roy. Soc. trop. Med. Hyg.* 63, 854–858 (1969).
- Schaefer H.: Über das Vorkommen von *Porocephalus moniliformis* in Kamerun. *Arch. Schiff's- u. Tropenhyg.* 16, 109–113 (1912).
- Seifert H.: Ein Beitrag zur Kenntnis des *Porocephalus moniliformis*. *Arch. Schiff's- u. Tropenhyg.* 14, 101–110 (1910).
- Seifert H.: Weitere Funde von *Porocephalus moniliformis* in Kamerun. *Arch. Schiff's- u. Tropenhyg.* 14, 506–514 (1910).
- Self J. R.: Pentastomiasis: host responses to larval and nymphal infections. *Trans. Amer. micros. Soc.* 91, 2–8 (1972).
- Self J. R., Hopps H. C., Williams A. O.: Porocephaliasis in man and experimental mice. *Exp. Parasit.* 32, 117–126 (1972).
- Smith J. A., Oladiran B., Langundye S. B., Lawson E. A. L., Francis T. I.: Pentastomiasis and malignancy. *Ann. trop. Med. Parasit.* 69, 503–512 (1975).
- Sonobe K.: Über Linguatuliden-Larven-Knötchen (sog. Pentostomenknötchen der Leber des Menschen). *Virchows Arch. path. Anat.* 263, 754–768 (1927).
- Symmers W. St. C.: Two cases of eosinophilic prostatitis due to metazoan infestation with *Oxyuris vermicularis*, and with a larva of *Linguatula serrata*. *J. Path. Bact.* 73, 549–555 (1957).
- Symmers W. St. C., Valteris K.: Two cases of human infestation by larvae of *Linguatula serrata*. *J. clin. Path.* 3, 212–219 (1950).
- Tiendrebeogo H., Levy D., Schmidt D.: La pentastomose humaine à Abidjan. *Rev. franç. Mal. resp.* 10, 351–358 (1982).
- Tobie J. E., Edgcomb J. H., Freireich E. J.: Tongue worm (*Linguatula serrata*) infestation in a patient with acute leucaemia. *Amer. J. clin. Path.* 28, 628–633 (1957).
- Vande Voorde R. R.: Un aspect chirurgical de la porocéphalose nymphale. *Ann. Soc. belge Méd. trop.* 36, 911–913 (1956).
- Van Wymeersch H., Wanson M.: La porocéphalose nymphale et son image radiologique. *Ann. Soc. belge Méd. trop.* 34, 517–522 (1954).
- Waldow: *Porocephalus moniliformis* bei einem Kamerunneger. *Arch. Schiff's- u. Tropenhyg.* 12, 321–324 (1908).
- Wilson A. H.: Notes on two cases of *Porocephalus armillatus* infection occurring in man. *Trop. Dis. Bull.* 6, 420 (1915), ref. Self et al. (1972).

