

Zeitschrift: Cahiers d'archéologie romande
Band: 51 (1990)

Artikel: Étude anthropologique
Rubrik: Planches
Autor: Kramar, Christiane
DOI: <https://doi.org/10.5169/seals-835464>

Nutzungsbedingungen

Die ETH-Bibliothek ist die Anbieterin der digitalisierten Zeitschriften. Sie besitzt keine Urheberrechte an den Zeitschriften und ist nicht verantwortlich für deren Inhalte. Die Rechte liegen in der Regel bei den Herausgebern beziehungsweise den externen Rechteinhabern. [Siehe Rechtliche Hinweise.](#)

Conditions d'utilisation

L'ETH Library est le fournisseur des revues numérisées. Elle ne détient aucun droit d'auteur sur les revues et n'est pas responsable de leur contenu. En règle générale, les droits sont détenus par les éditeurs ou les détenteurs de droits externes. [Voir Informations légales.](#)

Terms of use

The ETH Library is the provider of the digitised journals. It does not own any copyrights to the journals and is not responsible for their content. The rights usually lie with the publishers or the external rights holders. [See Legal notice.](#)

Download PDF: 06.10.2024

ETH-Bibliothek Zürich, E-Periodica, <https://www.e-periodica.ch>

PLANCHES

Planche 1 Tombe 1965-1: crâne 1.

Les crânes sont présentés selon les vues faciale, occipitale, supérieure, inférieure et latérale droite.

Planche 2 Tombe 4: crâne 24.

Planche 3 Tombe 9: crâne 31.

Planche 4 Tombe 9: crâne 32.

Planche 5 Tombe 10: crâne 35.

Planche 6 Tombe 16: crâne 44.

Planche 7 Extension interradiculaire de l'émail dentaire et pathologie dentaire.

Planche 8 Pathologie congénitale

- 1: atlas 1973-10 (vue supérieure)
- 2: sacrum 32 (vue postérieure)
- 3: patella 13 (vue antérieure).

Planche 9 Pathologie infectieuse: ostéomyélite chronique

- 1: tibia gauche 1973-3/3 (vue macroscopique antérieure)
- 2: vue radiologique (flèche: abcès centro-osseux).

Planche 10 Pathologie tumorale: fibrome utérin calcifié

- 1: vue macroscopique 100%
- 2: vue radiologique
- 3: microradiographie
- 4: image au microscope électronique (flèche: fibrilles de collagène, montrant une striation caractéristique).

Planche 11 Hyperostose du sujet 31

- 1: manubrium avec ossification chondrocostale (vue antérieure)
- 2: clavicule gauche: facette sternale
- 3: clavicule droite: tubérosité costale (vue inférieure)
- 4: segment thoracique, en vue latérale droite avec spondylose (les flèches montrent les ostéophytes)
- 5: vertèbre thoracique (vue inférieure): la flèche indique le listel marginal.

Planche 12 Trépanation: crâne 1965-T1

- 1: crâne en norma lateralis
- 2: vue «oblique» montrant la cicatrisation parfaite (flèche).

Planche 13 Matériel archéologique

- 1: boutons à perforation en V du type de Glis (T1)
- 2: bloc de cérusite moulé à la forme du contenant (T5)
- 3: poudre d'ocre solidifiée à la forme du contenant (T4)
- 4: perles discoïdes en lignite (T1)

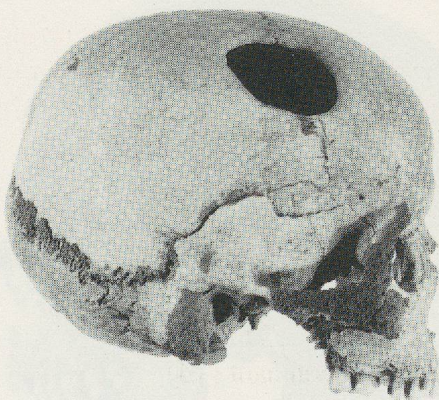
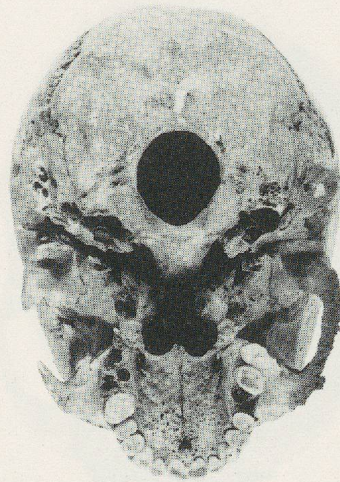
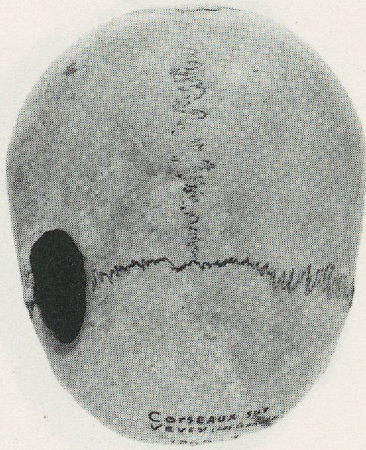
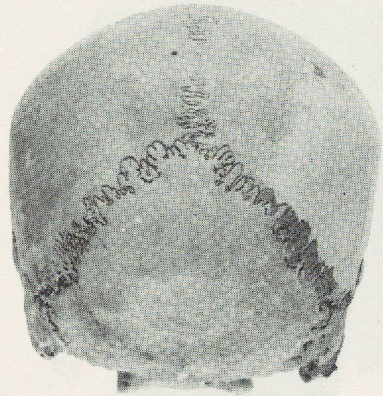
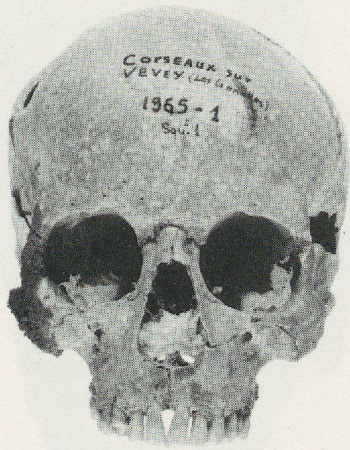

PLANCHE 1 : 1965-T3 CRANE 1

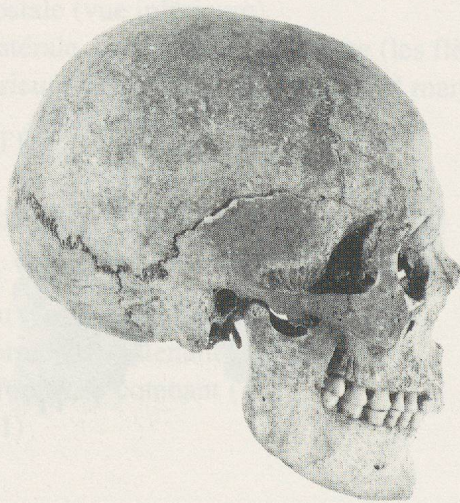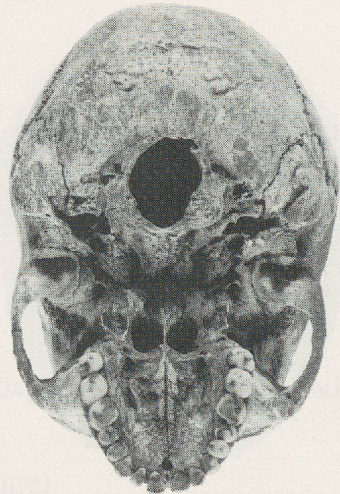
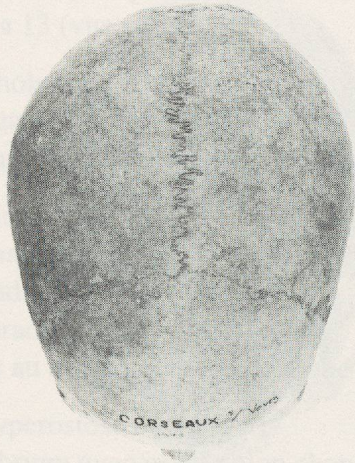
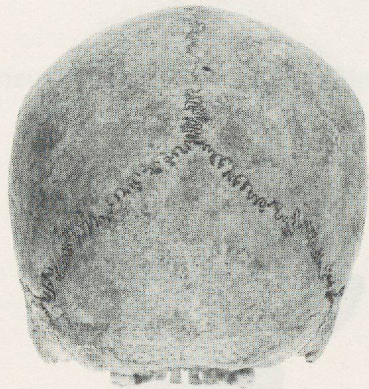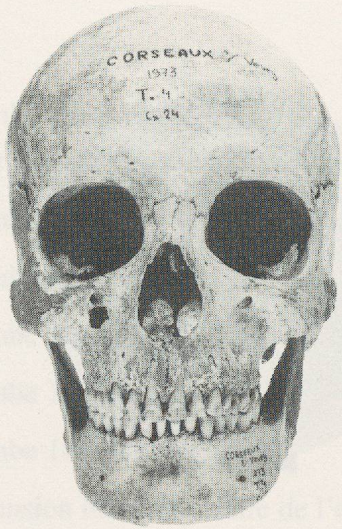


PLANCHE 2 : T4 CRANE 24

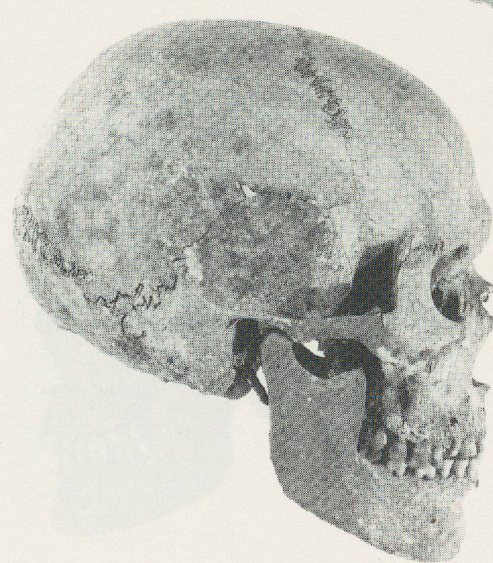
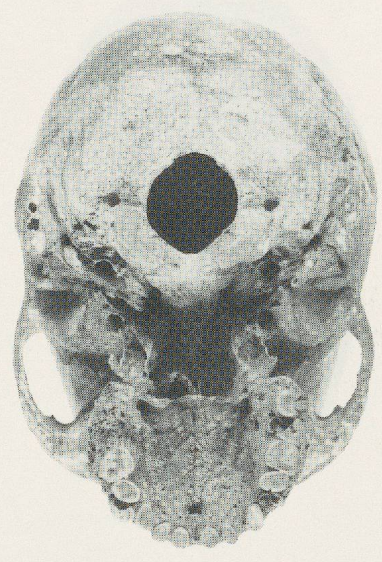
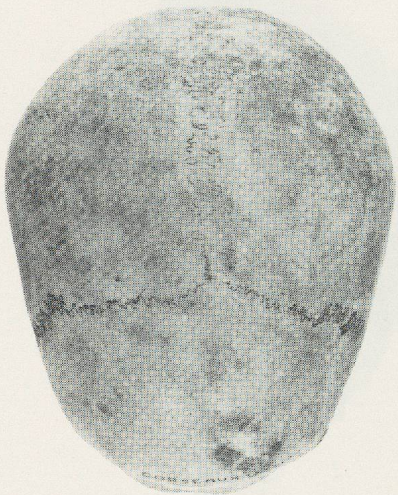
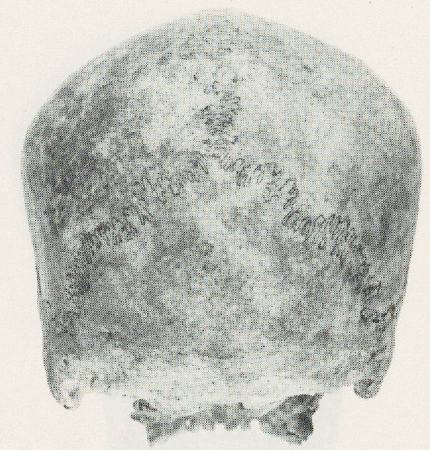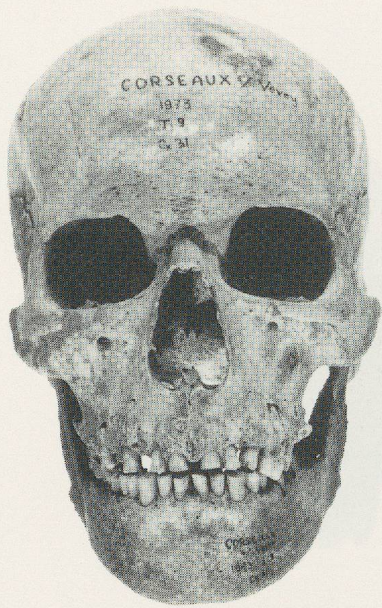


PLANCHE 3 : T9 CRANE 31

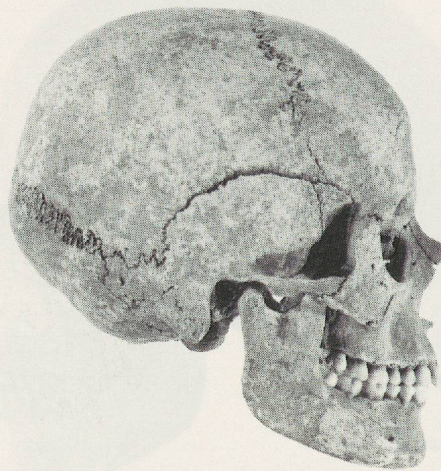
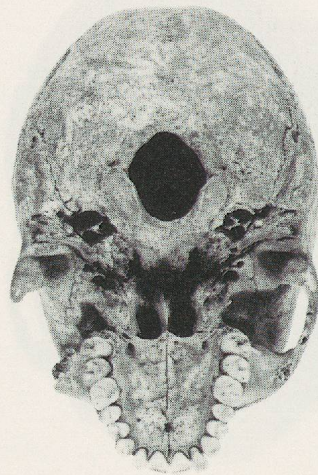
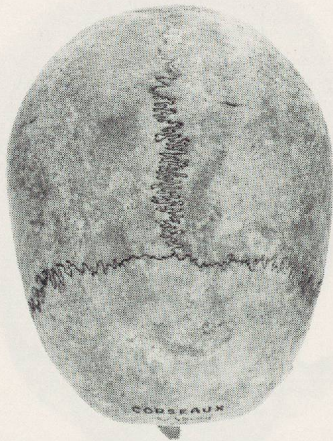

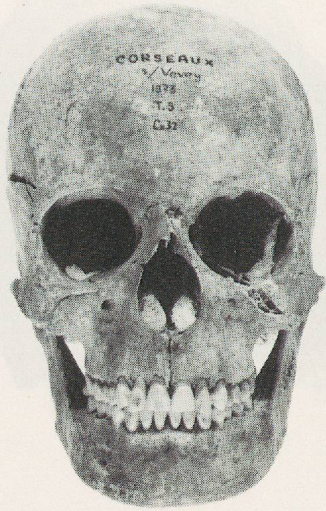


PLANCHE 4 : T9 CRANE 32

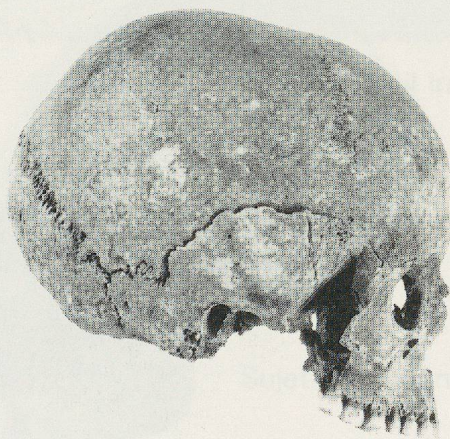
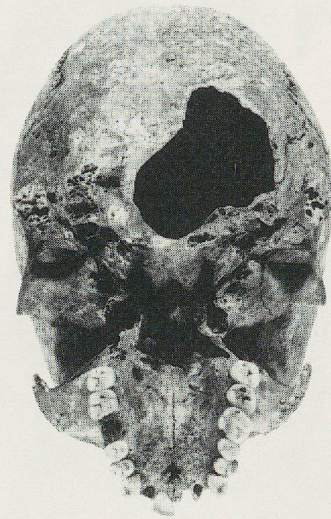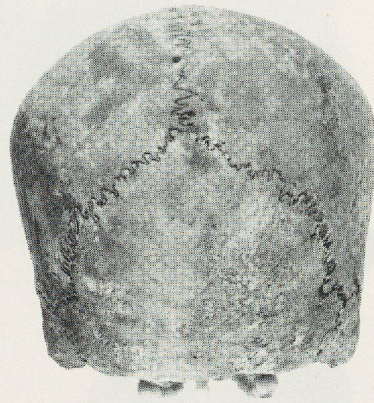
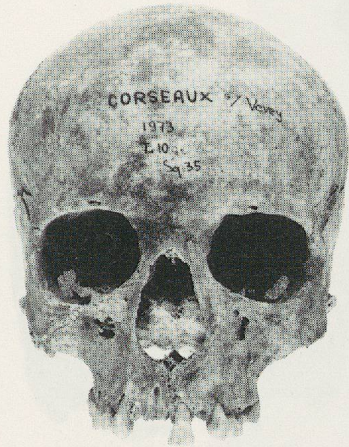


PLANCHE 5 : T 10 CRANE 35

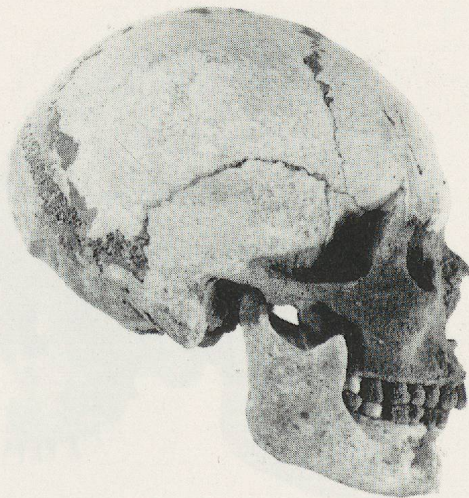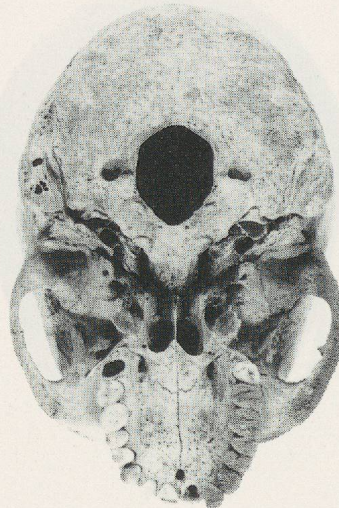
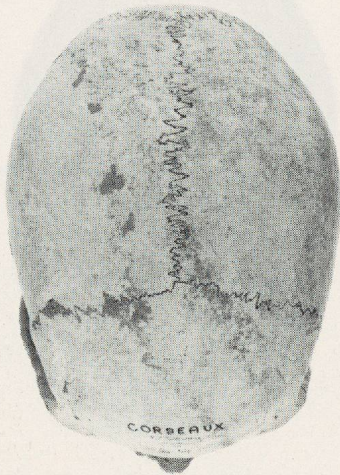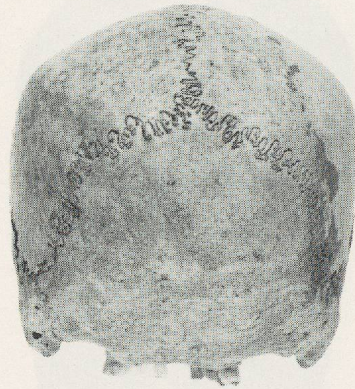
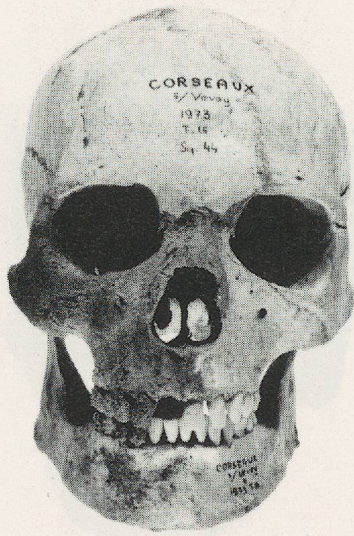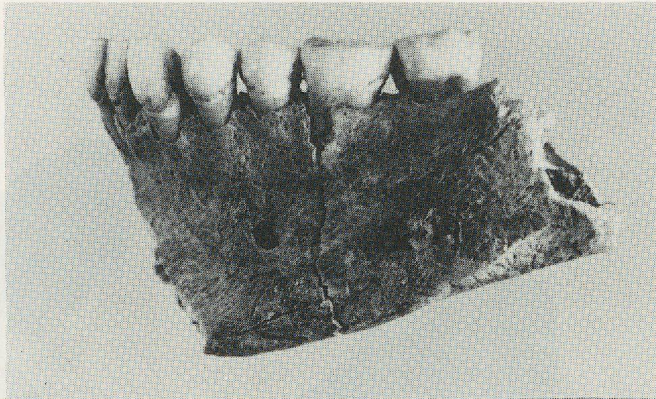


PLANCHE 6 : T16 CRANE 44

Sujet 14



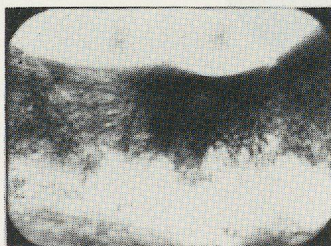Sujet 23



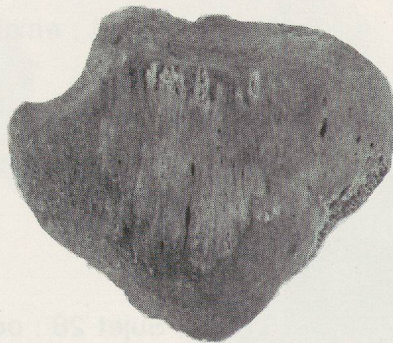
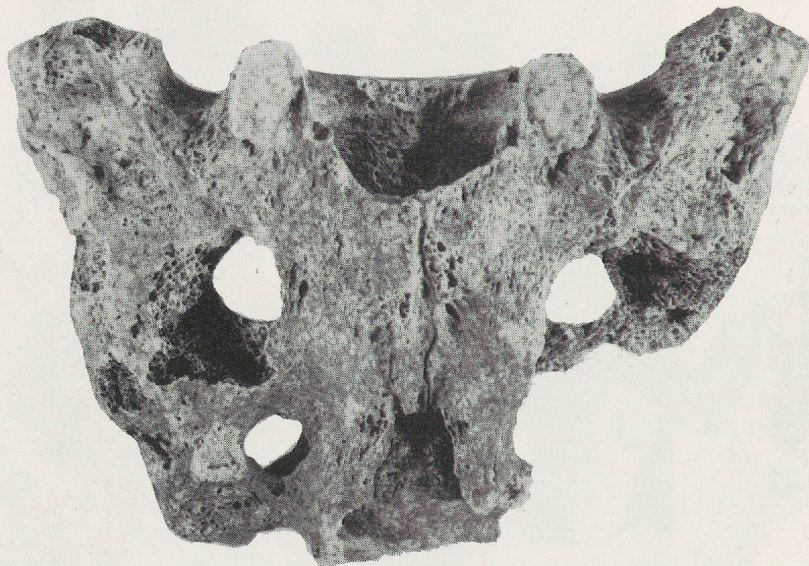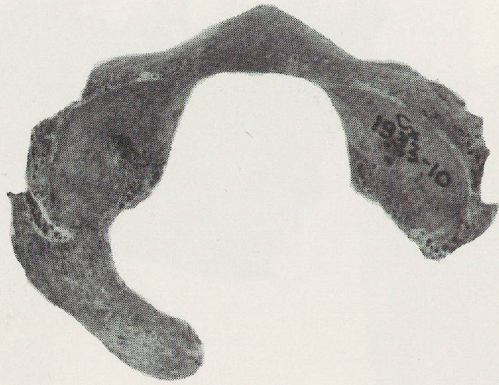Sujet 44



Sujets 14, 23, 44 : email interradiculaire




Sujet 28 : odontome eventuel ?



PLT PLANCHE 8 CRANE 44



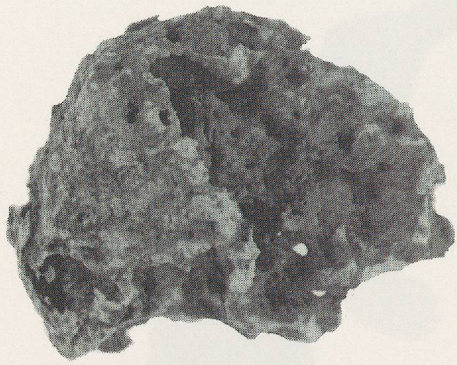1



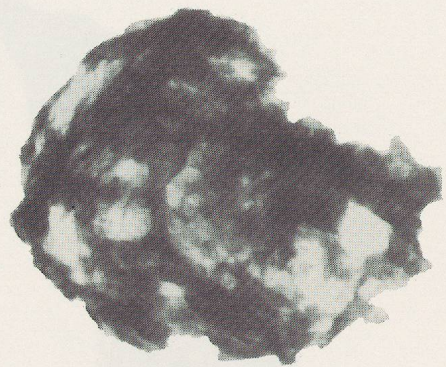
2

PLANCHE 9

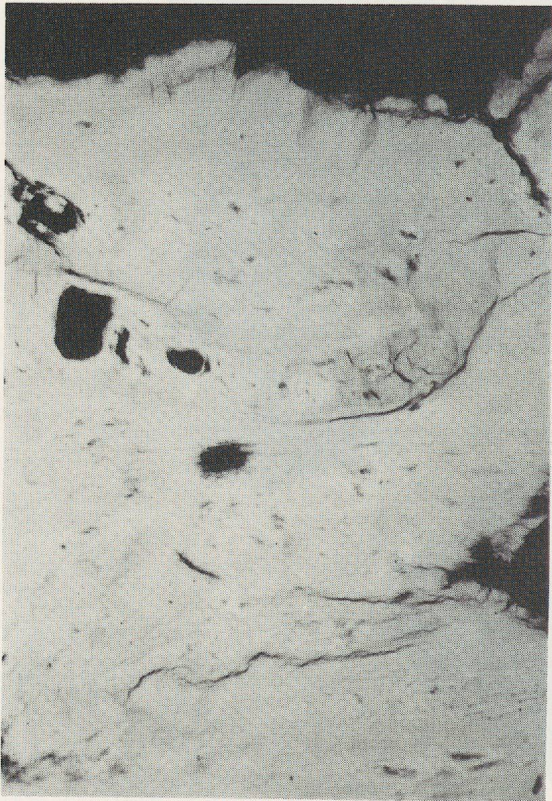
PLANCHE 11



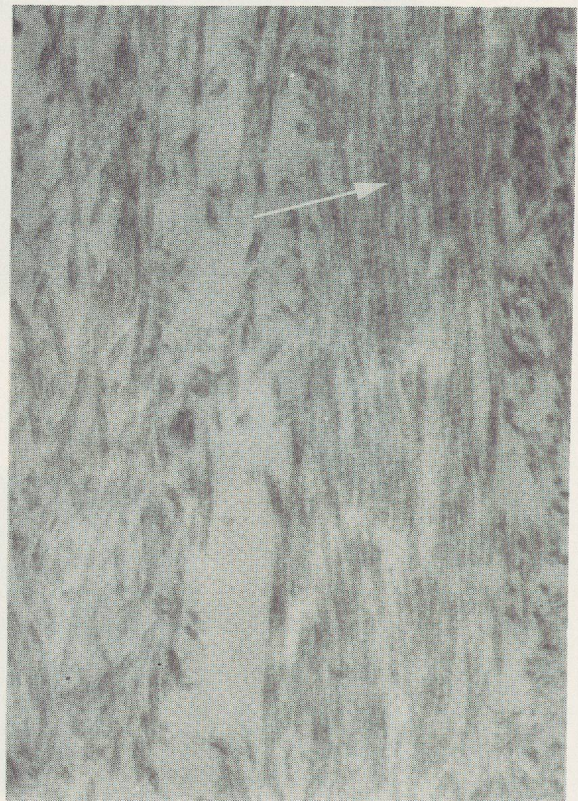
1



2

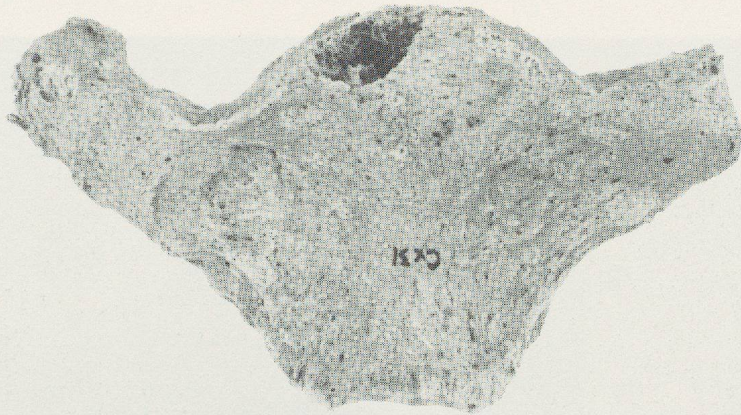

3




4

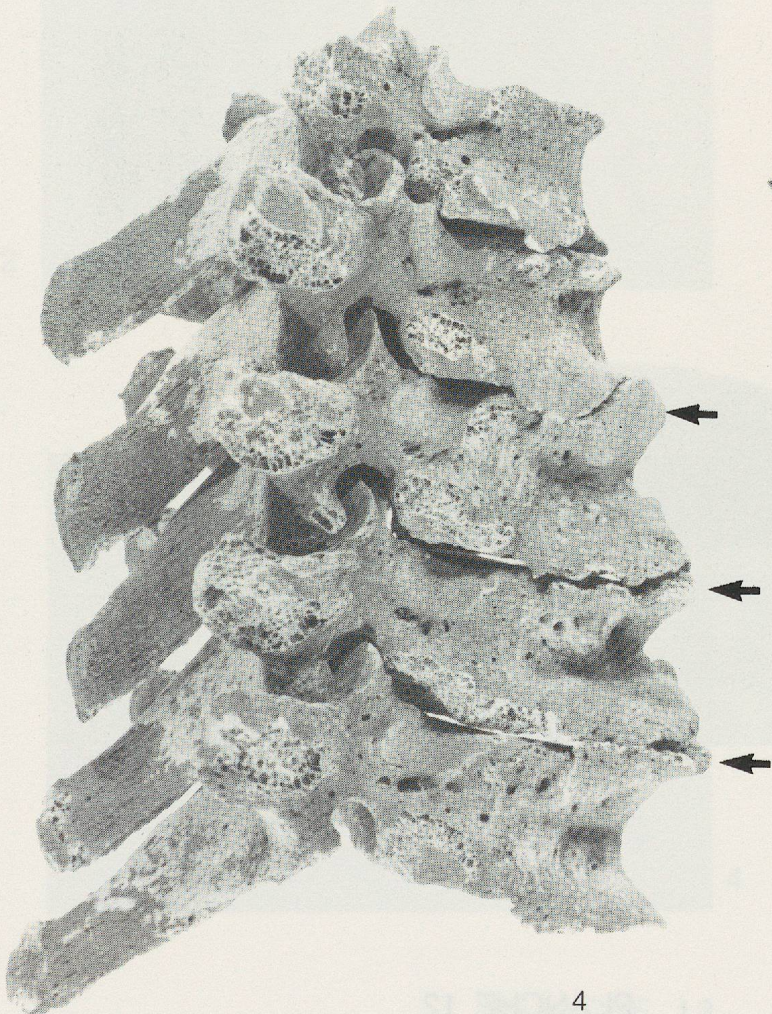
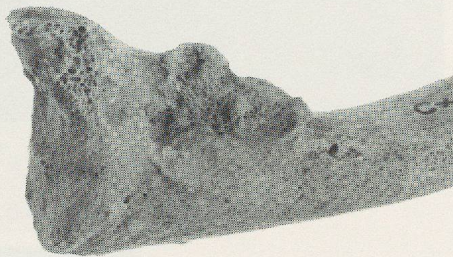
1



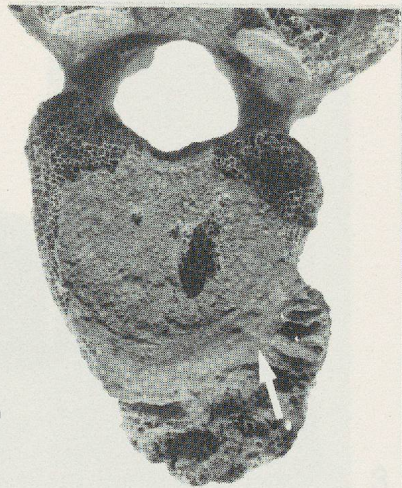
2



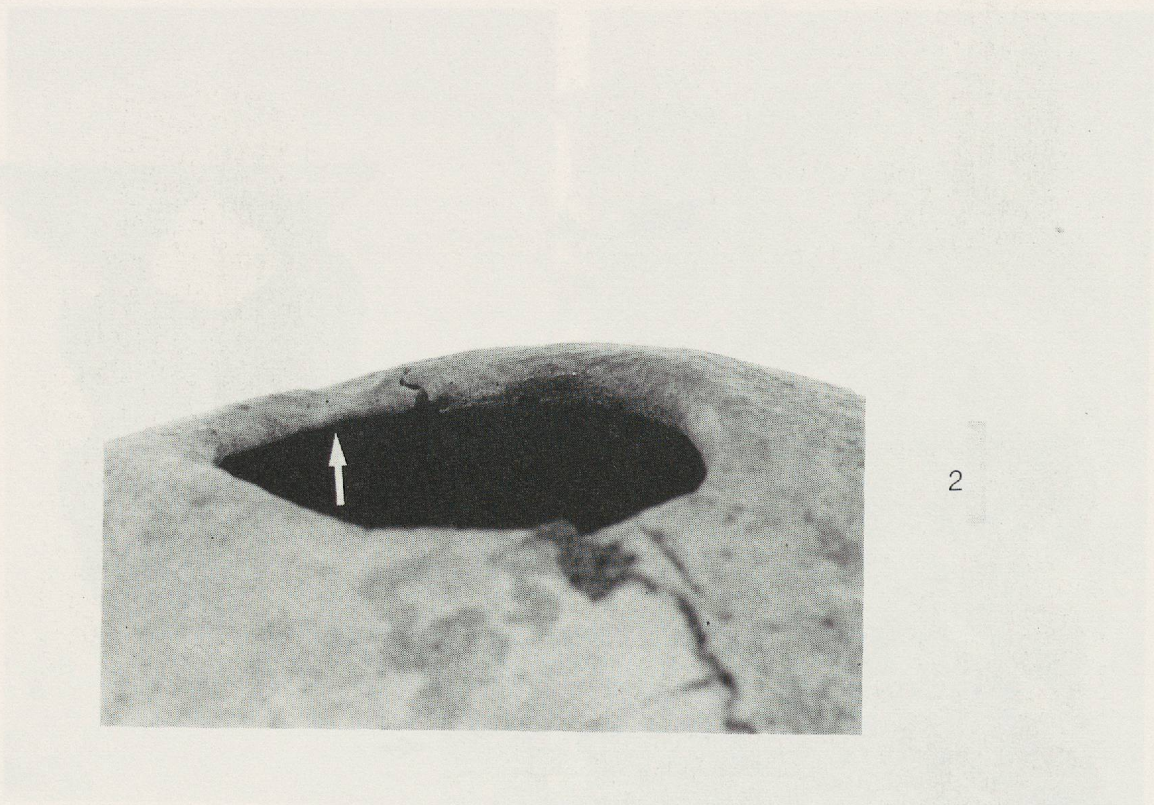
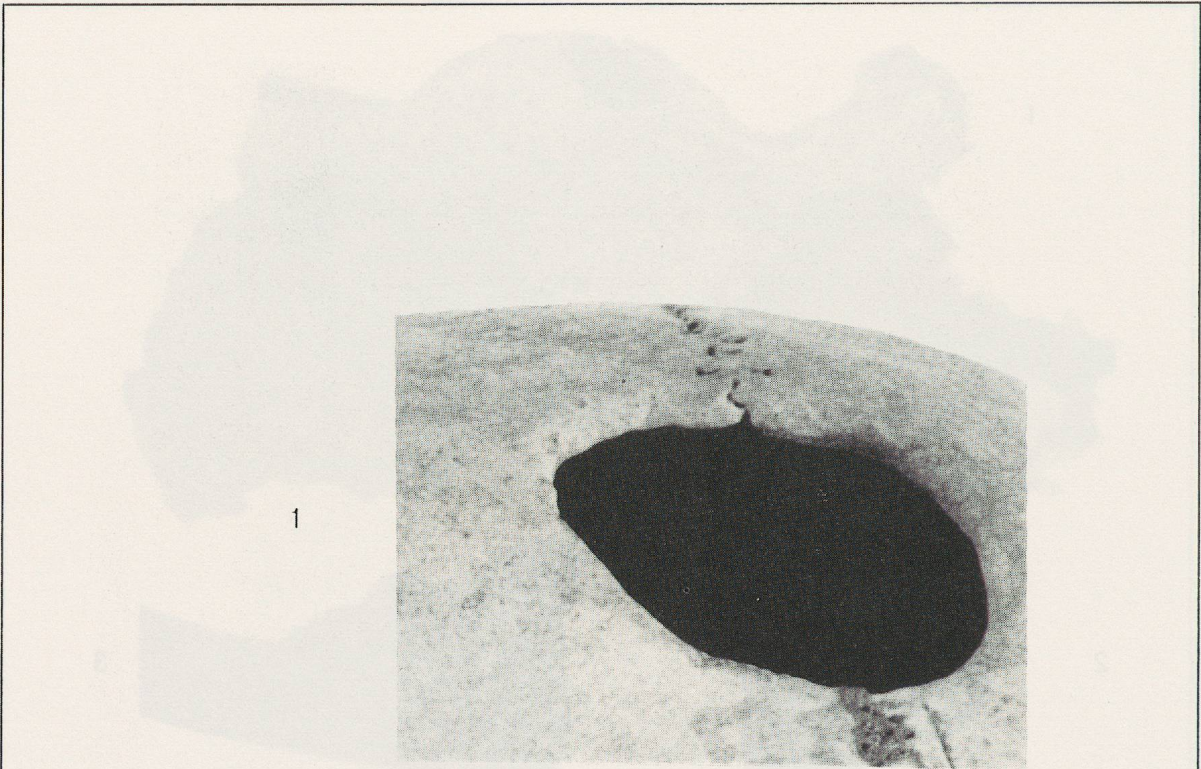
3

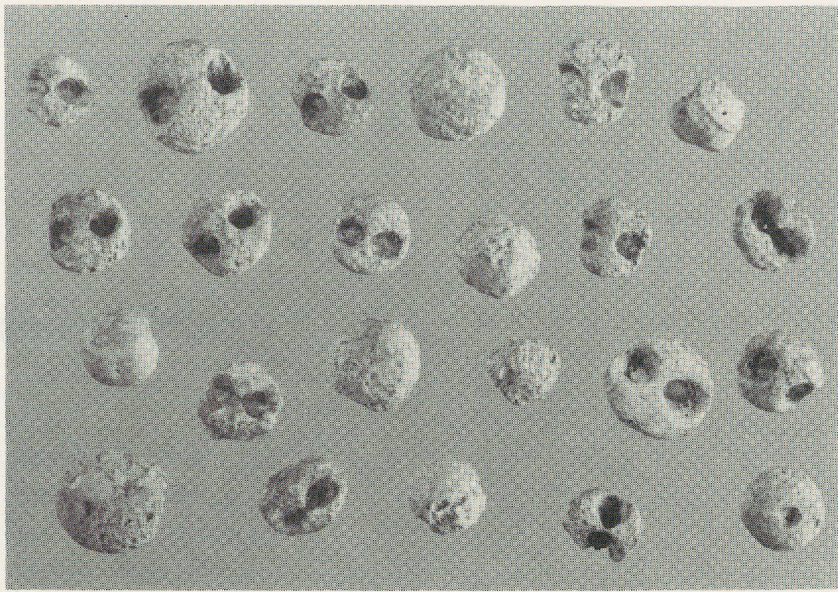


4




5







1



2



3



4

