

Zeitschrift: Schweizer Archiv für Tierheilkunde SAT : die Fachzeitschrift für Tierärztinnen und Tierärzte = Archives Suisses de Médecine Vétérinaire ASMV : la revue professionnelle des vétérinaires

Herausgeber: Gesellschaft Schweizer Tierärztinnen und Tierärzte

Band: 120 (1978)

Artikel: Malignant Mastocytosis and Duodenal Ulceration in a Cat

Autor: Hasler, Ursula C. / Ingh, T.S.G.A.M. van den

DOI: <https://doi.org/10.5169/seals-591911>

Nutzungsbedingungen

Die ETH-Bibliothek ist die Anbieterin der digitalisierten Zeitschriften. Sie besitzt keine Urheberrechte an den Zeitschriften und ist nicht verantwortlich für deren Inhalte. Die Rechte liegen in der Regel bei den Herausgebern beziehungsweise den externen Rechteinhabern. [Siehe Rechtliche Hinweise.](#)

Conditions d'utilisation

L'ETH Library est le fournisseur des revues numérisées. Elle ne détient aucun droit d'auteur sur les revues et n'est pas responsable de leur contenu. En règle générale, les droits sont détenus par les éditeurs ou les détenteurs de droits externes. [Voir Informations légales.](#)

Terms of use

The ETH Library is the provider of the digitised journals. It does not own any copyrights to the journals and is not responsible for their content. The rights usually lie with the publishers or the external rights holders. [See Legal notice.](#)

Download PDF: 06.02.2025

ETH-Bibliothek Zürich, E-Periodica, <https://www.e-periodica.ch>

Schweiz. Arch. Tierheilk. 120, 263–268, 1978

Institute of Animal Pathology, Faculty of Veterinary Medicine, Bern, Switzerland

Malignant Mastocytosis and Duodenal Ulceration in a Cat

by Ursula C. Hasler and T. S. G. A. M. van den Ingh¹

Introduction

Mast cell tumours are well known in domestic animals, especially in the dog (Jubb and Kennedy, 1970). In the dog they are found mainly in the skin (Gaudin, 1974); in the cat this form is less frequently seen, compared with systemic and disseminated mast cell neoplasms, so-called malignant mastocytosis (Nielsen, 1969; Saar et al., 1969; Garner and Lingeman, 1970; Jubb and Kennedy, 1970; Jarrett and Mackey, 1974).

In this paper malignant mastocytosis in a cat is described. The lesion was associated with duodenal ulceration and massive intestinal haemorrhage.

Case report

A 14-year-old spayed female cat showed anorexia for 2 weeks. The cat died unexpectedly without any further symptoms and was presented for autopsy.

Gross findings

The animal was in good bodily condition. The cadaver was pale, particularly as indicated by the colour of the mucous membranes. The blood was thin and watery. The skin and superficial lymph nodes showed no abnormalities. The abdominal cavity contained about 15 ml of clear, yellowish transudate. The liver was twice normal size and of a yellow-brown colour interspersed with greyish, miliary spots. The spleen was markedly enlarged (15x6 cm) and had a firm, elastic consistency with a greyish-red colour. The dorsal pole showed fibrous thickening of the splenic capsule. The cut surface exhibited a total loss of normal structure; instead, an almost diffuse, finely granular grey appearance was observed (Fig. 1). The left kidney had a large, wedge-shaped, organised infarct. The stomach was empty except for a small amount of bloodstained mucous. The small and large intestine contained much coagulated blood. Adjoining the orifice of the pancreatic duct was a large ulcer (1x0.3 cm) which extended deeply into the duodenal wall and was associated with erosion of a large blood vessel. The pancreas had multiple white nodules (0.1–0.2 cm) suggestive of nodular hyperplasia. The other organs, including the internal lymph nodes, showed no abnormalities.

¹ Address of authors: Postfach 2735, CH-3001 Bern

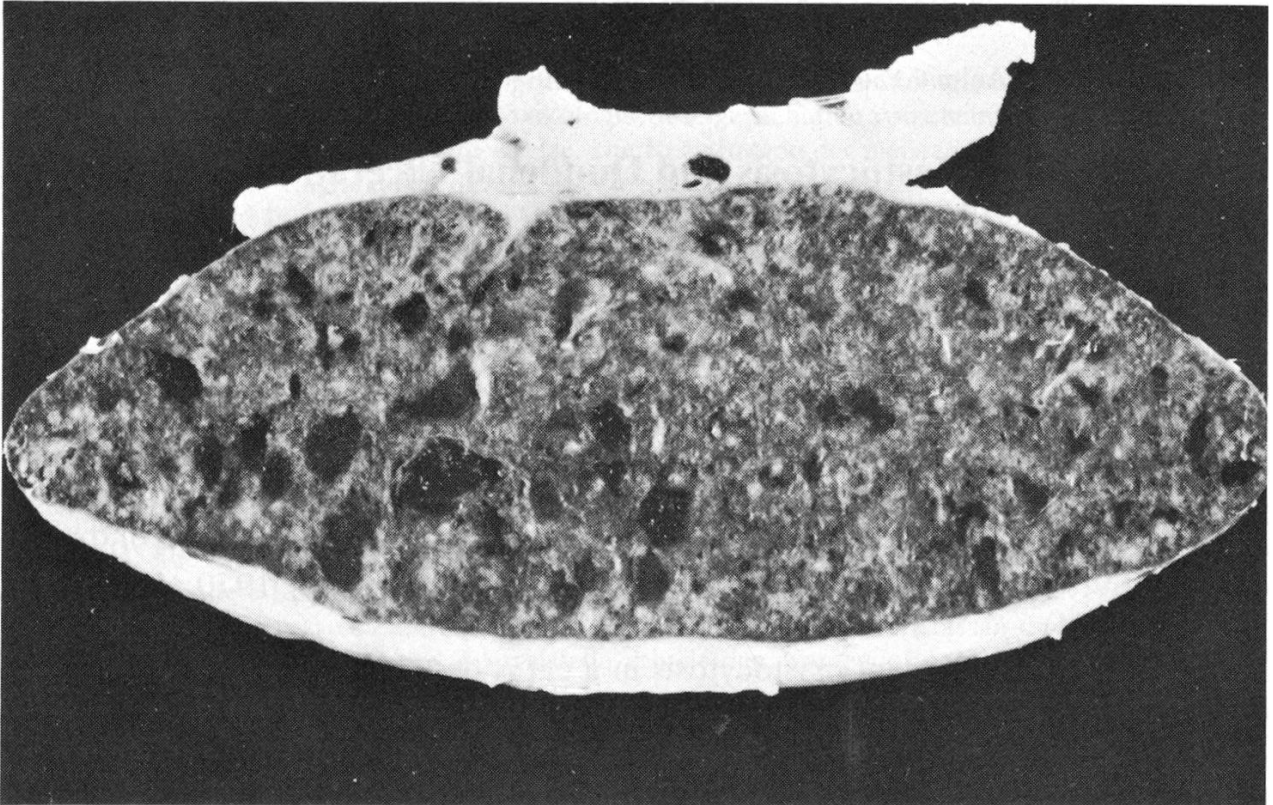


Fig 1 Spleen: markedly enlarged by diffuse infiltration of tumour cells, fibrous thickening of splenic capsule.

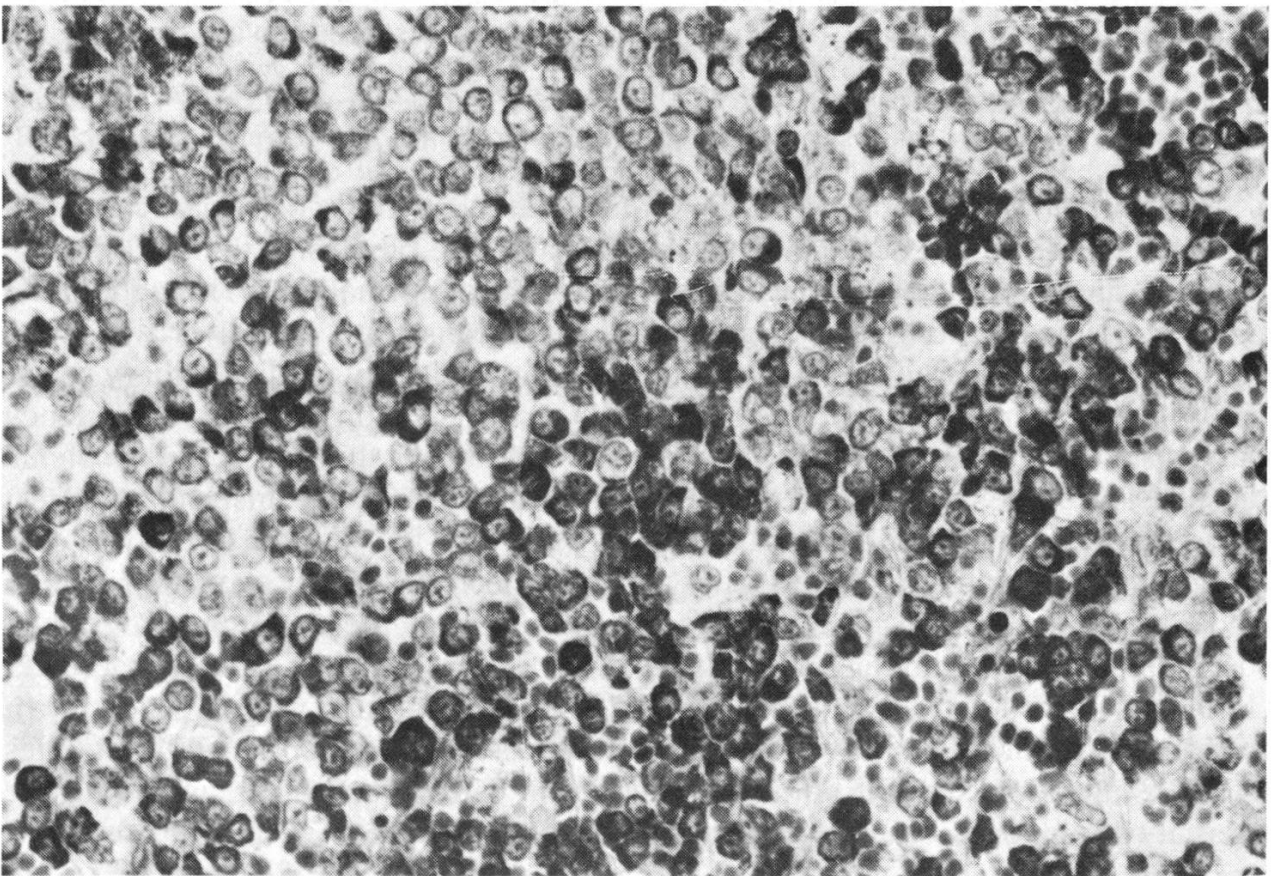


Fig. 2 Spleen: almost total replacement of red pulp by mast cells. Giemsa, 300x.

Microscopical findings

The red pulp of the *spleen* was almost totally replaced by neoplastic cells. Only a few lymphoid follicles and periarterial lymphoid sheaths remained, and those, too, were invaded by tumour cells. The malignant cells were polygonal and had a pale and finely granular cytoplasm; their nuclei were round to oval with finely dispersed chromatin and a small nucleolus. Both with toluidine-blue and Giemsa staining the tumour cells showed distinct metachromatic granules characteristic of mast cells. Most cells were of a mature type (Fig. 2). The *liver* showed a diffuse infiltration of identical tumour cells. Solitary cells and small to moderate aggregations were found within the liver sinuses; larger foci were present in the portal triads where there was some bile duct proliferation. Within the tumour foci some lymphocytes and, occasionally, eosinophilic granulocytes were observed; mitotic figures were rare. Tumour cells were observed in some hepatic veins. Moreover, pigmentation of centrilobular liver cells and pigment-laden Kupffer cells were seen. The *lungs* showed hyperplasia of the musculature of the small bronchi and slight hyperplasia of bronchial glands. Some small, peribronchial, lymphocytic foci were present. Rarely some tumour cells were observed in blood vessels. The *stomach* exhibited a mild focal, superficial lymphoid infiltration of the mucosa. There was also focal calcification just beneath the mucosal surface at the neck of the crypts. Many bi- and multinucleated parietal cells were seen suggestive of hyperplasia (Fig. 3). In the *duodenum* the ulcer extended into the musculature and was filled with necrotic debris, fibrin, erythrocytes and a moderate number of neutrophilic granulocytes. A large necrotic vessel, from which bleeding possibly had occurred, could be distinguished in this mass (Fig. 4). The surrounding granulation tissue consisted of many neocapillaries with proliferative endothelial cells, histiocytes, fibroblasts, granulocytes and a few lymphocytes. Moreover, small arteries showed medial hyperplasia and proliferative endothelium with constriction of the lumen. This focal granulation tissue extended into the subserosa. No abnormal accumulations of mast cells were present in the granulation tissue nor in the surrounding intestinal wall. Throughout the small and large intestine, blood was present in the lumen; no other abnormalities were seen in the intestinal wall.

One *kidney* contained a scarred infarct and slight calcification of the medulla. The *heart* showed lipomatosis of the outer zone of the myocardium with loss of muscular tissue. The *adrenal glands* showed diffuse and nodular cortical hyperplasia and hyperplasia and calcification of the medullary zone. The thyroid was normal.

Discussion

The neoplastic cells described are histologically identical with mast cells and because of the distribution of the neoplastic lesions the diagnosis malignant mastocytosis was made (Jarrett and Mackey, 1974). As reported by others (Lapie and Fontaine, 1969; Saar et al., 1969; Goto et al., 1974) the spleen and liver contained the most prominent lesions. In most cases the mesenteric lymph nodes are usually

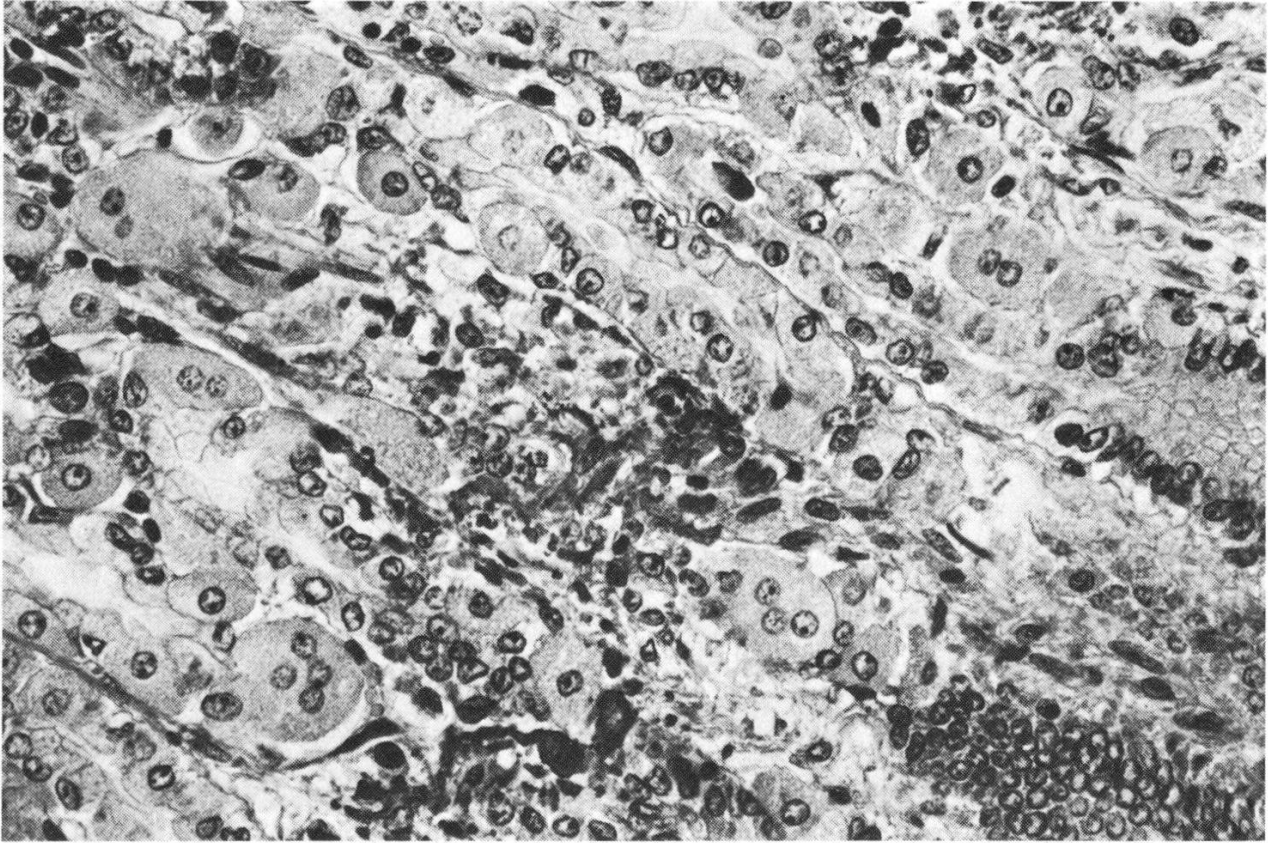


Fig. 3 Stomach: multiple bi- and multi-nucleated parietal cells together with calcium deposition (arrow). HE, 350x.

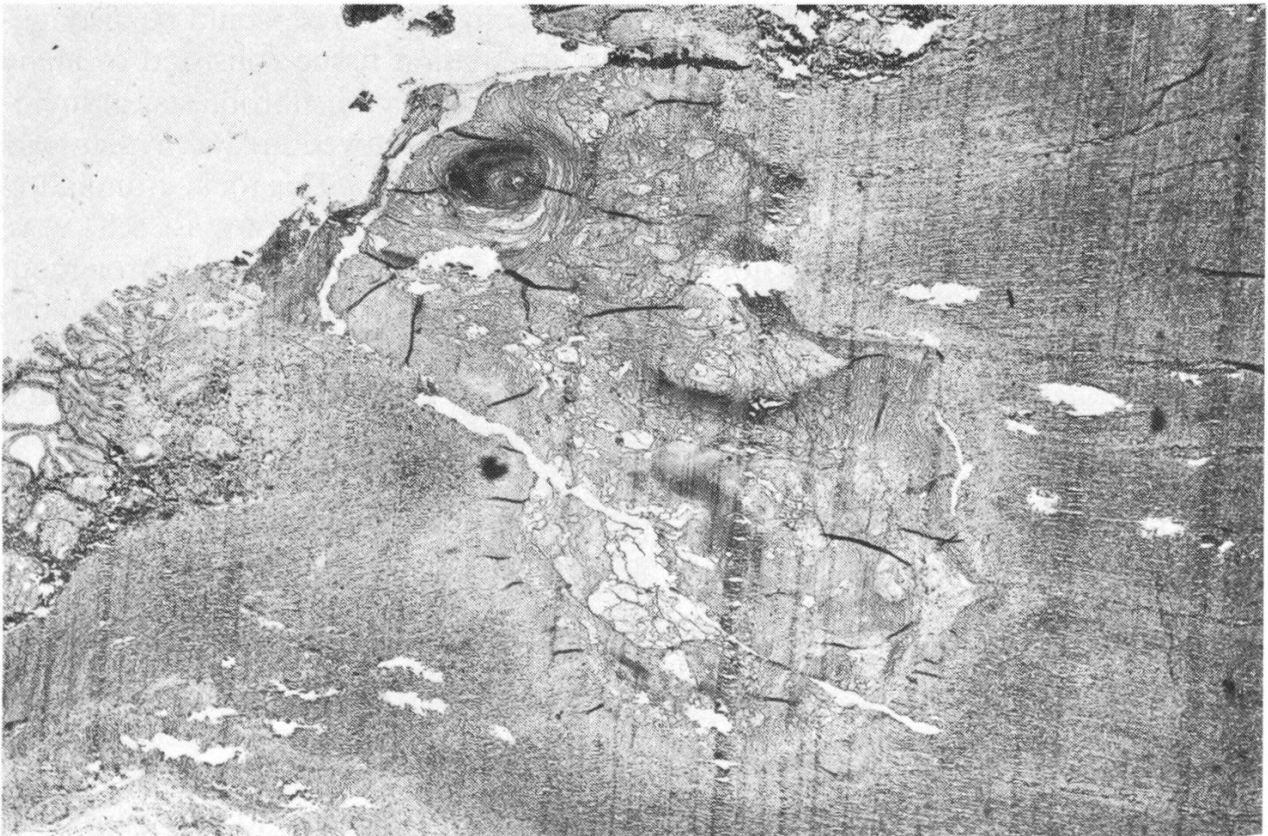


Fig. 4 Duodenum: ulcer with necrotic vessel (arrow). HE, 20x.

also affected, although gross lesions occur in only a small percentage of cases (*Goto et al.*, 1974). In the present case the mesenteric lymph nodes showed no gross lesions and histological examination was not performed.

Howard et al. (1969) reported a very high incidence of gastroduodenal ulceration in dogs with mast cell neoplasia. Although feline mastocytosis is relatively frequent (*Saar et al.*, 1969; *Garner and Lingeman*, 1970; *Goto et al.*, 1974), only a few cases of gastric (*Schalm*, 1961) or duodenal (*Seawright and Grono*, 1964; *Smith et al.*, 1972) ulceration have been observed as a complication of mast cell neoplasia in the cat.

The mechanism of induction of the gastroduodenal ulcers is not completely understood. In man duodenal ulceration is associated with increased gastric acidity and, histologically, the stomach shows an increase of parietal cells (*Soulé et al.*, 1977). This probably results from chronic neural or humoral stimulation (*Kirsner*, 1967). A well known stimulus for gastric acid secretion is histamine and experimentally, repeated injections of histamine resulted in gastroduodenal erosion and ulceration in various animals (*Jones*, 1957; *Howard et al.*, 1969). In the cat, mast cell tumours are mostly very rich in histamine and contain very little of the anti-coagulant heparin (*Riley*, 1959). Mast cell neoplasms may therefore be the origin of chronic histaminemia, which may give rise to hyperplasia of parietal cells with increased gastric acidity and subsequent (gastro)duodenal ulceration. The multiple bi- and multi-nucleated parietal cells in the gastric mucosa of our cat suggest a similar pathogenesis. Whether the vascular changes contribute to the pathogenesis of the gastroduodenal ulceration (*Howard et al.*, 1969) is not clear as similar changes may be found secondarily in reactive inflammation.

Summary

Malignant mastocytosis in a cat is described. The lesion was associated with duodenal ulceration and massive intestinal haemorrhage.

Zusammenfassung

Ein Fall maligner Mastozytose bei der Katze wird beschrieben. Die neoplastischen Veränderungen waren begleitet von Duodenal-Ulzeration und massiver Darmblutung.

Résumé

Les auteurs décrivent un cas de mastocytose maligne chez une chatte. Les altérations néoplasiques étaient accompagnées d'un ulcère duodénal et d'une hémorragie intestinale massive.

Riassunto

Si descrive un caso di mastocitosi maligna nel gatto. Le alterazioni neoplastiche erano accompagnate da un'ulcera duodenale e da una emorragia intestinale massiva.

Literature

Garner F. M. and Lingeman C. H.: Mast cell neoplasms of the domestic cat. *Path. vet.* 7, 517–530 (1970). – *Gaudin G. J. L.*: Contribution à l'étude épidémiologique et anatomo-pathologique du mastocytome du chien. Thèse Ecole Nationale Vétérinaire Alfort (1974). – *Goto N., Ozasa M., Takahasi R., Ishida K. and Fujiwara K.*: Pathological observations of feline mast cell tumor. *Jap. J. vet. Sci.* 36, 483–494 (1974). – *Howard E. B., Sawa T. R., Nielsen S. W. and Kenyon A. J.*: Mastocytoma and gastroduodenal ulceration. *Path. vet.* 6, 146–158 (1969). – *Jarrett W. F. H. and Mackey L. J.*:

Neoplastic diseases of the haematopoietic and lymphoid tissues. Bull. Wld. Hlth. Org. 50, 21–34 (1974). – Jones L. M.: Veterinary pharmacology and therapeutics. 2nd ed., Ames, Iowa, p. 303 (1957). – Jubb K. V. F. and Kennedy P. C.: Pathology of domestic animals. 2nd ed., Academic Press, New York and London, vol. 2, p. 648 (1970). – Kirsner J. B.: in: Pathologic physiology, eds. Sodeman and Sodeman. 4th ed., W. B. Saunders Company, Philadelphia and London, pp. 579–582 (1967). – Labie C. H. et Fontaine M.: Mastocytome splénique du chat. Bull. Acad. Vét. France 33, 361–366 (1960). – Nielsen S. W.: Spontaneous hematopoietic neoplasms of the domestic cat. Nat. Cancer Inst. Monogr. 32, 73–94 (1969). – Riley J. F.: The mast cells. E. and S. Livingstone Ltd., Edinburgh and London, pp. 87–89 (1959). – Saar Chr., Opitz M., Lange W., Hirschert R., Burow H., Grund S. and Loppnow H.: Mastzellenretikulose bei Katzen. Berl. Münch. tierärztl. Wschr. 82, 438–444, 449–456 (1969). – Schalm O. W.: Veterinary haematology. Lea and Febiger, Philadelphia, pp. 303–304 (1961). – Seawright A. A. and Grono L. R.: Malignant mast cell tumour in a cat with perforating duodenal ulcer. J. Path. Bact. 87, 107–111 (1964). – Smith H. A., Jones T. C. and Hunt R. D.: Veterinary pathology. 4th ed., Lea and Febiger, Philadelphia, p. 1210 (1972). – Soulé J. C., Accary J. P. et Mignon M.: Signification physiopathologique des hypergastrinémies chez l'homme. Gastroentérol. Clin. Biol. 1, 171–186 (1977).

REFERATE

Zur Verbreitung der Schweinebesamung in Europa, 1976

Land	Anzahl Erstbesamungen	KB in % aller Belegungen	Durch Besitzer ausgeführte Besamungen (% aller Besamungen)
Finnland	64 690	33	10
Schweden	20 479	4	7
Norwegen	56 217	41	0
Dänemark	355 000	21	10
Grossbritannien	66 607	4	76
Niederlande	191 285	13	3
Deutschland (BRD)	195 600	5	15
Belgien	10 291	0,05	0
Frankreich	101 000	2–3	21
Schweiz	14 133	4	48
Österreich	41 607	3	40

(28. Jahrestagung der Europ. Vereinigung für Tierzucht, Brüssel)

(SVZ-Inform. Nr. 25/1978)

Reinzucht – Quo vadis?

- Von den reinen Braunviehkühen werden nur noch 50,4% rein weitergezüchtet.
- Die Zahl der besamten Tiere mit Brown-Swiss-Blut hat sich innerhalb Jahresfrist mehr als verdoppelt (von 5698 auf 13 093).
- Bei Simmentaler Fleckvieh beträgt der Anteil der Reinzuchtpaarungen noch 50,6%.
- Der Bestand an besamten Red-Holstein-Kreuzungstieren stieg auf 38 297 Stück.

(Aus den KB-Mitteilungen des SVKB, 16.1.1978)