

# Chronic Small Airway Disease in Horses Slaughtered in Switzerland

Autor(en): **Winder, N. Christine / Fellenberg, R. von**

Objektyp: **Article**

Zeitschrift: **Schweizer Archiv für Tierheilkunde SAT : die Fachzeitschrift für Tierärztinnen und Tierärzte = Archives Suisses de Médecine Vétérinaire ASMV : la revue professionnelle des vétérinaires**

Band (Jahr): **129 (1987)**

PDF erstellt am: **25.07.2024**

Persistenter Link: <https://doi.org/10.5169/seals-593379>

## **Nutzungsbedingungen**

Die ETH-Bibliothek ist Anbieterin der digitalisierten Zeitschriften. Sie besitzt keine Urheberrechte an den Inhalten der Zeitschriften. Die Rechte liegen in der Regel bei den Herausgebern.

Die auf der Plattform e-periodica veröffentlichten Dokumente stehen für nicht-kommerzielle Zwecke in Lehre und Forschung sowie für die private Nutzung frei zur Verfügung. Einzelne Dateien oder Ausdrucke aus diesem Angebot können zusammen mit diesen Nutzungsbedingungen und den korrekten Herkunftsbezeichnungen weitergegeben werden.

Das Veröffentlichen von Bildern in Print- und Online-Publikationen ist nur mit vorheriger Genehmigung der Rechteinhaber erlaubt. Die systematische Speicherung von Teilen des elektronischen Angebots auf anderen Servern bedarf ebenfalls des schriftlichen Einverständnisses der Rechteinhaber.

## **Haftungsausschluss**

Alle Angaben erfolgen ohne Gewähr für Vollständigkeit oder Richtigkeit. Es wird keine Haftung übernommen für Schäden durch die Verwendung von Informationen aus diesem Online-Angebot oder durch das Fehlen von Informationen. Dies gilt auch für Inhalte Dritter, die über dieses Angebot zugänglich sind.

Schweiz. Arch. Tierheilk. 129, 585–593, 1987

Institute of Veterinary Physiology, University of Zurich, Switzerland

## Chronic Small Airway Disease in Horses Slaughtered in Switzerland

N. Christine Winder and R. von Fellenberg\*

### Introduction

Chronic small airway disease is the most common abnormality of the equine respiratory system (Cook, 1975) and has been considered to be the most frequent cause of premature retirement in the Swiss horse population (Gerber, 1969). In Australia, where horses are kept primarily outside, the incidence of chronic small airway disease is low. In many parts of Europe and in the northern United States, where many horses are stabled indoors for most of the day, the incidence of this respiratory syndrome is high (Anon., 1985). Although chronic small airway disease is thought to be associated with exposure of horses to straw, hay and stable dust (Cook and Rossdale, 1963; Lowell, 1964; Gillespie and Tyler, 1969; Eyre, 1972; Gerber, 1973; Schatzmann *et al.*, 1974; McPherson *et al.*, 1979), the pathogenesis of the disease remains obscure. A consistent finding is chronic bronchiolitis (Gerber, 1973; Viel, 1983; Anon., 1985; Winder, 1987).

In this report, the incidence and pulmonary pathology of chronic small airway disease was studied in horses slaughtered over a one year period in northeastern Switzerland.

### Materials and methods

#### *Tissues*

Pulmonary specimens were obtained from 115 horses slaughtered from October 1984 to October 1985 at the Veterinary Teaching Hospital, University of Zurich.

After visual and physical examination of the lungs, lung specimens were collected from the apical, ventral, dorsal and diaphragmatic regions and from areas with gross lesions. Specimens of trachea, major bronchi and tracheobronchial lymph nodes also were collected. Specimens were fixed in 10 per cent phosphate buffered formalin, embedded in paraffin, sectioned at 3 to 5  $\mu\text{m}$  and stained with hematoxylin and eosin (H & E), periodic acid-Schiff (PAS) and van Gieson stains.

### Evaluation of Specimens

A minimum of eight parenchymal lung sections per horse were H & E stained and examined at 40 $\times$ , 100 $\times$ , 200 $\times$ , 400 $\times$  and 1000 $\times$  magnification. Sections which best represented each horse's lung histology were stained with PAS and van Gieson stains for assessment of goblet cell hyperplasia and fibrosis, respectively. Based on the predominant histological lesion in the lungs, horses were grouped into one of the following categories: normal, chronic small airway disease, interstitial pneumonia, pulmonary eosinophilic infiltration, pulmonary hemorrhage and suppurative bronchopne-

---

\* Address: Winterthurerstrasse 260, CH-8057 Zürich

monia. Horses with chronic small airway disease were further categorized according to the severity of pulmonary lesions into mild, moderate or severe chronic small airway disease using grading criteria described by *Viel* (1983).

## Results

Reasons for slaughter of the 115 horses included lameness (51.3%), colic (17.4%), chronic respiratory disease (9.6%, of which 63.6% were due to chronic small airway disease), a variety of medical reasons (13.9%) and unknown grounds (7.8%).

Histological examination of the lungs resulted in six groups which are listed in Table 1. Horses with chronic small airway disease comprised the largest group (43 horses; 37.4%). Fourteen of the 43 horses had either clinical diagnoses (seven horses) or owner's histories (seven horses) of moderate or severe chronic pulmonary disease. Mild lesions (22 horses) were more common than moderate (13 horses) or severe (8 horses) lesions in horses with chronic small airway disease. As the severity of the disease increased so did the incidence of gross pulmonary lesions; lungs of horses with moderate and severe chronic small airway disease were generally voluminous and pale pink. There was often copious mucus in the airways and hypertrophy of tracheobronchial lymph nodes. Mild fibrinous pleuritis and fibrous tags were sometimes observed on the ventral diaphragmatic lung surface.

Histological lesions in horses with mild chronic small airway disease included slight epithelial and goblet cell hyperplasia, mild smooth muscle hypertrophy, predominantly around terminal bronchioles, and lymphocytic infiltration around bronchioles and vasculature. Aggregates of lymphocytes, forming small nodules were seen around bronchioles in six horses. Lesions were invariably worse in the caudal lung half. In lungs with moderate chronic small airway disease, airway epithelial hyperplasia and squamous metaplasia were more pronounced and affected more airways than in lungs with mild histological lesions. There was goblet cell hyperplasia in small bronchi, bronchioles and sometimes terminal bronchioles. Mucus and neutrophils occluded airway lumina. Lymphocytes and plasma cells formed thick peribronchiolar cuffs. Peribron-

Table 1: Histological categories and age of 115 horses slaughtered at the Veterinary Teaching Hospital, University of Zurich.

Histological category	No of horses	% of total	Average age (yr)
Normal	31	27.0	9.5
Chronic small airway disease (total)	43	37.4	13.2
mild lesions	22	19.1	12.2
moderate lesions	13	11.3	13.1
severe lesions	8	7.0	14.4
Interstitial pneumonia	18	15.6	9.9
Pulmonary eosinophilic infiltration	16	13.9	9.1
Pulmonary hemorrhage	4	3.5	9.7
Bronchopneumonia	3	2.6	9.7

chiolar lymphoid hyperplasia, in the form of nodules and follicles, was seen in five horses. Hemosiderin-laden macrophages were sometimes observed around bronchioles and in alveoli (Fig. 1). Lungs of horses with severe histopathology (Figs. 2, 3 and 4) included the lesions described for horses with moderate chronic small airway disease; however, lesions were diffuse and also included perivascular and peribronchiolar fibrosis, peribronchiolar alveolar epithelial hyperplasia and alveolar septal thickening with mononuclear cells and fibrous tissue.

Of the 18 horses with interstitial pneumonia (15.6%), 8 (6.9%) had either owner's histories (4 horses) or clinical diagnoses (4 horses) of chronic pulmonary disease. The clinical symptoms were indistinguishable from those of horses with chronic small airway disease except for 1 horse in which thoracic radiographs revealed severe interstitial pneumonia. Histologically, these horses had chronic granulomatous bronchointerstitial pneumonia (3 horses), chronic diffuse bronchointerstitial pneumonia (4 horses) or chronic focal interstitial pneumonia (1 horse).

### Discussion

The high incidence of chronic small airway disease is in agreement with previous observations in Switzerland (*Gerber, 1969*) and in Europe (*Anon., 1985*). Lack of pasture space in some European regions necessitates that many horses remain stabled for most of the day. Stable dusts, especially from hay and straw, if not directly involved in the etiology of this respiratory syndrome, could act as physical irritants and exacerbate already existing disease (*Lazary et al., 1973*).

Of the 43 horses with histological lesions of chronic small airway disease, only 14 had histories of respiratory impairment. These horses had either moderate or severe histological lesions. Due to the large reserve capacity of the equine lung, early or mild pulmonary changes may not be detectable clinically (*Muyelle et al., 1972*). Subclinical chronic small airway disease may be diagnosed by bronchoalveolar lavage or a nitrogen washout test (*Viel, 1983*). However both tests are not routinely used in a clinical examination. This study indicates that chronic small airway disease and chronic interstitial pneumonia may be clinically indistinguishable using routine lung function tests. Other diagnostic procedures such as chest radiography or lung biopsy may be necessary to correctly differentiate the two.

In this study, the identification of horses with mild chronic small airway disease was based on histological lesions described by *Viel (1983)*. The most prominent changes were mild lymphocytic infiltration around bronchioles and vasculature and slight epithelial and goblet cell hyperplasia. These lesions increased in severity in horses with moderate and severe chronic small airway disease. The causes of epithelial and goblet cell hyperplasia in these horses are not known. Chemical, physical and viral agents may increase the number and activity of goblet cells and cause superficial epithelial cell desquamation with subsequent regeneration which may result in squamous metaplasia (*Bang and Bang, 1963, Falk et al., 1963*). Possible physical irritants in horses may be stable dust or hay and straw particles. Influenza virus infection has been implicated in the pathogenesis of chronic small airway disease (*Gerber, 1969, Thorsen et al., 1983*). It is

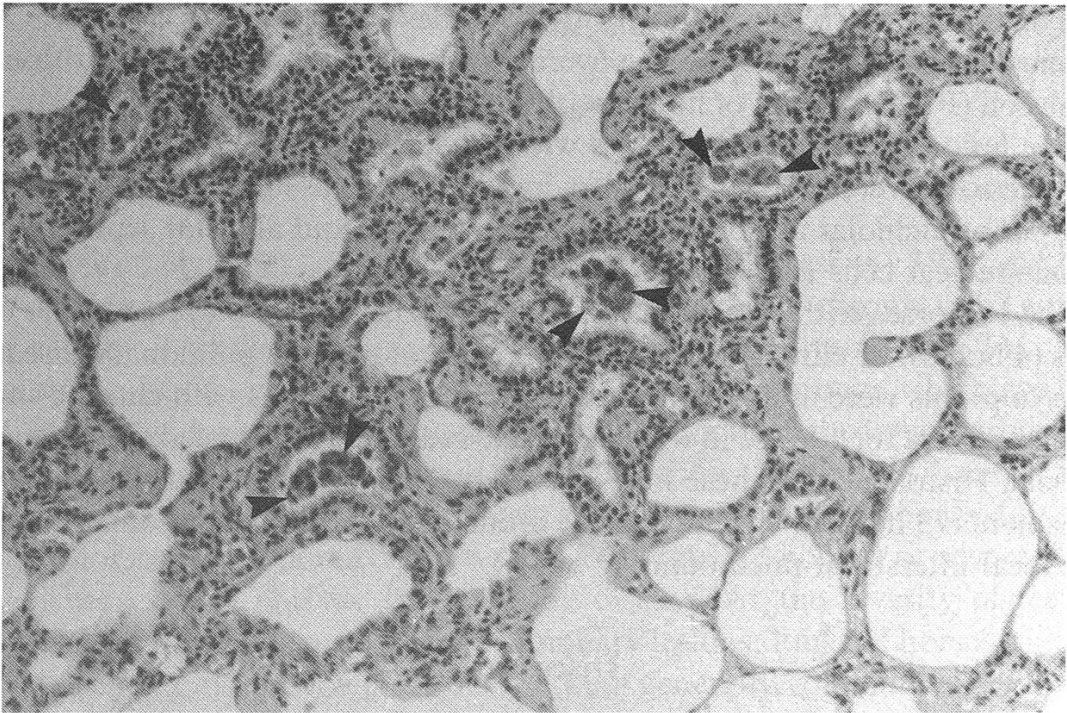


Figure 1: Specimen of lung parenchyma from the caudal diaphragmatic lobe in a horse with chronic small airway disease. Thickening of alveolar septa with mononuclear cells and fibrosis, intraalveolar hemosiderin-laden macrophages (arrows) and alveolar epithelial hyperplasia. Hematoxylin and eosin (H & E);  $\times 137$ .

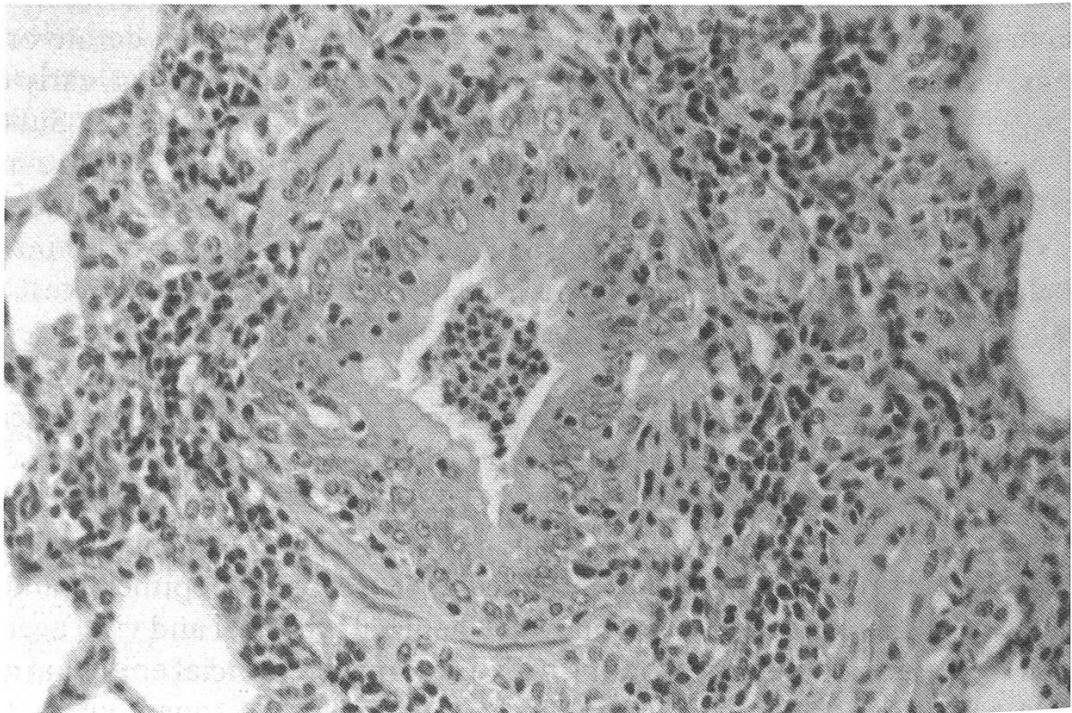


Figure 2: Specimen of a bronchiole in a horse with severe chronic small airway disease. Goblet cell hyperplasia, epithelial hyperplasia, interepithelial and intraluminal neutrophils, peribronchiolar mononuclear cell infiltration and peribronchiolar alveolar epithelial hyperplasia are evident. H & E;  $\times 137$ .

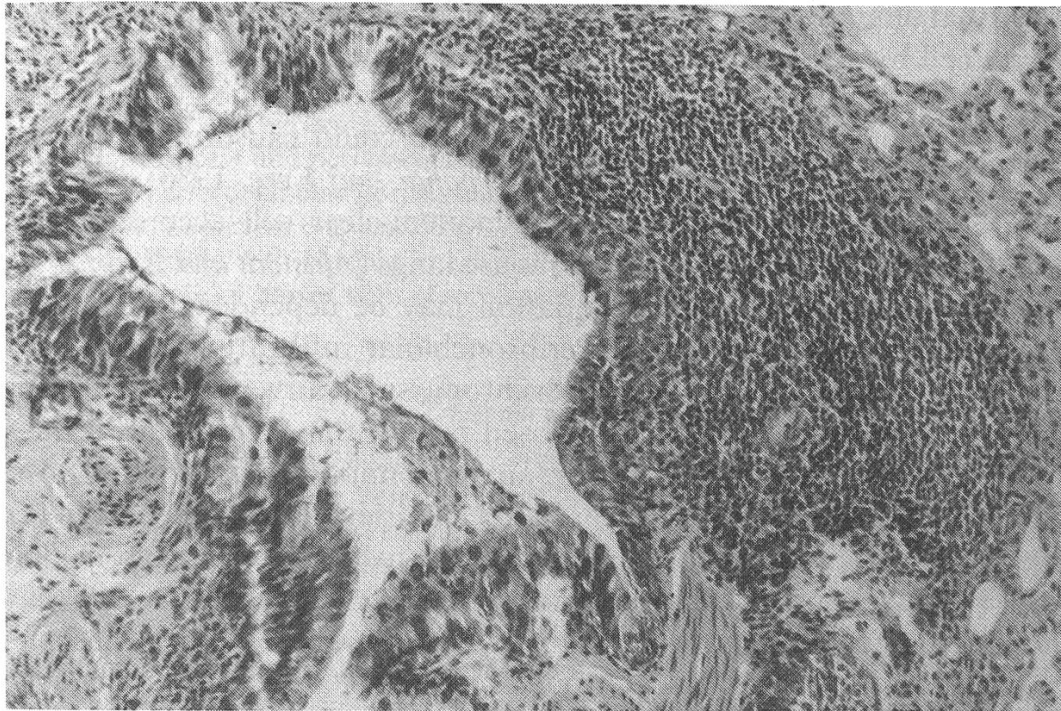


Figure 3: Specimen of a bronchiole in a horse with severe chronic small airway disease. Bronchiolar epithelial hyperplasia, intraluminal debris and a peribronchiolar lymphocytic follicle are evident. H & E;  $\times 137$ .

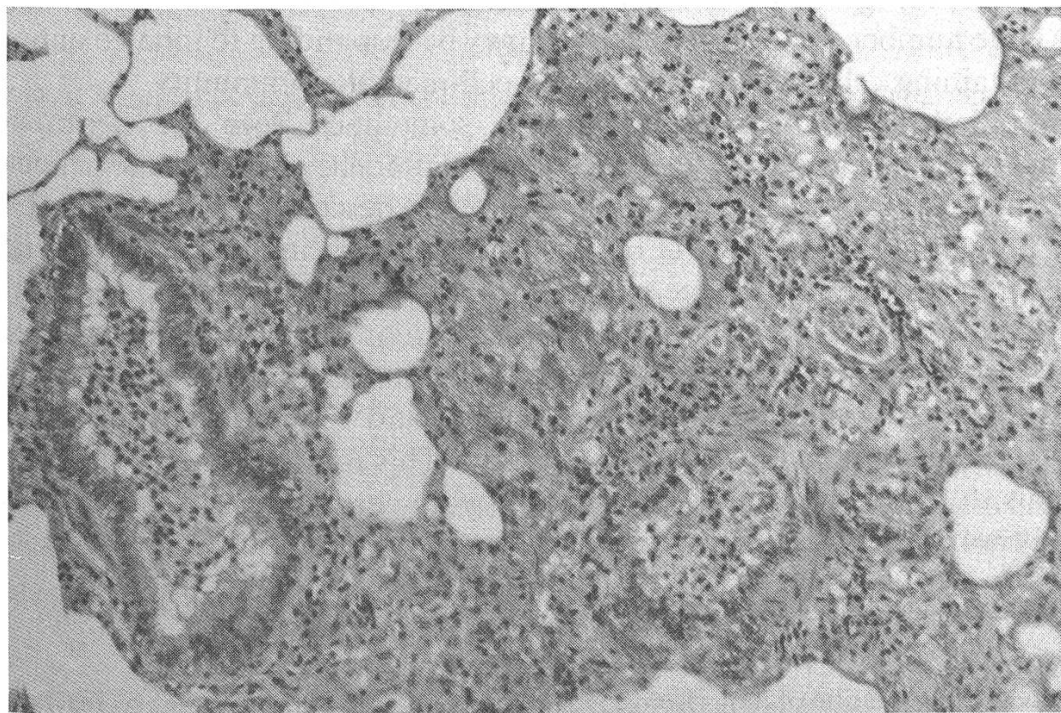


Figure 4: Specimen of two bronchioles and adjacent lung parenchyma in a horse with severe chronic small airway disease. Bronchiolar epithelial hyperplasia, intraluminal mucus and neutrophils and intraalveolar mucus accumulation are seen. H & E;  $\times 137$ .

conceivable that alterations in the mucociliary clearance mechanisms which are reflected by goblet cell hyperplasia and epithelial metaplasia could result in viral retention and in an increase in time available for virus release from mucoprotein (Falk *et al.*, 1963). Retention of other inhaled substances also could cause prolonged antigenic stimulation leading to hypersensitization (Mirbahar and Eyre, 1986). A close association between goblet cell hyperplasia and mononuclear cell accumulation around bronchioles has been observed in rat and mouse lungs (Ahlstedt and Enander, 1987). It was concluded that goblet cell differentiation may be dependent on environmental antigens and peribronchiolar T cells. Peribronchiolar infiltration with mononuclear cells was a prominent feature in horses with chronic small airway disease; however, it is not known whether T lymphocytes composed part of this cellular infiltrate.

Many neutrophils were observed in the airway lumina of horses with moderate and severe chronic small airway disease. This has been observed by other researchers (Gerber, 1973; Schoon and Deegen, 1983; Viel, 1983; Winder, 1987). Lysosomal proteases (Cochrane, 1968) and/or enzymes generating reactive O<sub>2</sub> metabolites (Johnson and Ward, 1981) released by neutrophils may be partly responsible for the chronic airway inflammation. Damage caused by neutrophil proteases has been questioned, however, because respiratory secretions of horses with severe chronic small airway disease contain protease inhibitory activity as well as protease activity (Grünig *et al.*, 1985).

The number of lymphocytes and plasma cells and the appearance of follicular structures increased with the severity of the pulmonary lesions. Immunohistochemical studies have shown that many of these cells contain immunoglobulin (Ig) A and IgG (Fc) and that most of the cells composing peribronchiolar follicles and nodules do not stain positively for Ig (Winder and von Fellenberg, 1986; Winder, 1987). It was suggested that the large number of Ig-containing cells may be responding to inhaled antigen. The non-Ig-containing cells may be involved in cell-mediated immunity.

Hemosiderin-laden macrophages were sometimes seen in peribronchiolar interstitial tissue and in alveoli. Evidence of old pulmonary hemorrhage in horses with chronic small airway disease has been previously described (Viel, 1983). Exercise-induced pulmonary hemorrhage (EIPH) is common in racing horses and its incidence increases with age and with degree of exertion (Pascoe *et al.*, 1981; Dungworth, 1985). It has been proposed that small airway disease may initiate the pathological changes leading to EIPH (Pascoe *et al.*, 1986). Scintigraphy in horses with EIPH has revealed unmatched deficits in pulmonary arterial perfusion and ventilation in the dorsocaudal area of the caudal lung lobe (Pascoe *et al.*, 1986). This is interesting in view of the fact that in this study, pulmonary lesions in horses with chronic small airway disease were invariably worse in the caudal lung half.

### Summary

Histological evaluation of lungs from 115 horses slaughtered at the Veterinary Teaching Hospital, University of Zürich resulted in six groups: normal (27%), chronic small airway disease (37.4%), interstitial pneumonia (15.6%), pulmonary eosinophilic infiltration (13.9%), pulmonary hemorrhage (3.5%) and suppurative bronchopneumonia (2.6%). In lungs with chronic small airway disease, mild lesions (51.2%) were more common than moderate (30.2%) or severe (18.6%) lesions. Slight goblet cell

and epithelial hyperplasia, mild smooth muscle hypertrophy predominantly around terminal bronchioles and lymphocytic infiltration around bronchioles and vasculature were seen in lungs with mild chronic small airway disease. These lesions progressed to marked epithelial hyperplasia and metaplasia and goblet cell hyperplasia, occlusion of airway lumina with neutrophils and mucus, prominent peribronchiolar and perivascular lymphocytic cuffing and hyperplastic lymphocytic follicles and nodules, peribronchiolar fibrosis and alveolar epithelial hyperplasia and thickening of alveolar septa with mononuclear cells and fibrous tissue in lungs with severe chronic small airway disease. Eight horses (6.9%) with chronic interstitial pneumonia had clinical signs which were indistinguishable from those of horses with chronic small airway disease.

### Zusammenfassung

Die histopathologische Beurteilung von 115 Pferdungen aus dem Schlachtlokal des Tierspitals Zürich ergab sechs Gruppen: Ohne Veränderungen (27%), mit chronischer Bronchiolitis (37.4%), mit interstitieller Pneumonie (15.6%), mit eosinophiler Lungeninfiltration (13.9%), mit Lungenblutungen (3.5%) und mit eitriger Bronchopneumonie (2.6%). In der Gruppe mit chronischer Bronchiolitis waren 51.2% mit leichtgradigen, 30.2% mit mittelgradigen und 18.2% mit hochgradigen Veränderungen. Leichte Becherzell- und Epithelzellhyperplasie, geringgradige Hypertrophie der glatten Muskulatur der terminalen Bronchiolen und der kleinen Gefäße wurden in den Lungen mit leichtgradiger Bronchiolitis beobachtet. Die Veränderungen entwickelten sich zu ausgesprochener Epithelzellhyperplasie und -metaplasie, Becherzellhyperplasie, Verschluss der kleinen Atemwege mit neutrophilen Granulozyten und Schleim, peribronchiolären und perivaskulären Lymphozytenansammlungen mit Knötchen, Follikelbildung, peribronchiolärer Fibrose, Hyperplasie der Alveolarzellen verbunden mit einer Verdickung der Septen durch mononukleäre Zellen und Bindegewebe in Lungen mit hochgradiger Bronchiolitis. Die Krankheitszeichen in vivo von acht Pferden (6.9%) mit chronischer interstitieller Pneumonie waren mit denen der chronischen Bronchiolitis identisch.

### Résumé

L'examen histopathologique de 115 poumons de chevaux provenant de l'abattoir du Tierspital de Zurich a permis de constituer 6 groupes: sans altérations (27%), avec bronchiolite chronique (37,4%), avec pneumonie interstitielle (15,6%), avec infiltration pulmonaire éosinophile (13,9%), avec hémorragies pulmonaires (3,5%), et avec broncho-pneumonie purulente (2,6%). Dans le groupe avec bronchiolite chronique, 51,2% étaient légèrement atteints, 30,2% moyennement et 18,2% gravement. Dans les cas de bronchiolite sans gravité, on a observé une légère hyperplasie des cellules caliciformes et épithéliales, et une légère hypertrophie de la musculature lisse des bronchioles terminales et des petits vaisseaux. Dans les cas graves, les altérations évoluaient vers une hyper- et métaplasie prononcée des cellules épithéliales, hyperplasie des cellules caliciformes, obstruction des voies respiratoires inférieures par des granulocytes neutrophiles et du mucus, accumulation pérbronchiolaire et périvascularaire de lymphocytes avec petits nodules, formation de follicules, fibrose pérbronchiolaire, hyperplasie des cellules alvéolaires liée à un épaississement des septes par des cellules mononucléées et du tissu conjonctif. In vivo, les symptômes de huit chevaux (6,9%) souffrant de pneumonie interstitielle chronique étaient identiques à ceux présents dans les cas de bronchiolite chronique.

### Riassunto

L'esame istologico di 115 polmoni di cavallo provenienti dal macello della Facoltà Veterinaria di Zurigo diede 6 gruppi: senza alterazioni (27%), con bronchiolite cronica (37,4%), con polmonite interstiziale (15,6%), infiltrazioni eosinofile (13,9%), emorragie (3,5%) e broncopolmonite purulenta (2,6%). Nel gruppo delle bronchioliti croniche 51,2% erano leggere, 30,2% di grado medio, e 18,2% presentavano forti alterazioni. Nei polmoni con leggera bronchiolite vennero individuate leggera



iperplasia delle cellule a calice ed epiteliali, leggera iperplasia della muscolatura liscia dei bronchioli terminali e dei piccoli vasi. Le lesioni si svilupparono in evidenti iperplasie e metaplasia delle cellule epiteliali, in iperplasia delle cellule a calice, in chiusura delle piccole vie respiratorie con granulociti neutrofili e muco, ammassi peribronchiali e perivascolari linfocitarie con noduli, formazioni follicolari, fibrosi peribronchiali, iperplasia delle cellule alveolari abbinate ad un ispessimento dei setti con cellule mononucleari e tessuto connettivo dei polmoni con forte bronchiolite. I sintomi di malattia in vivo di 8 cavalli (6,9%) con polmonite interstiziale cronica furono identici ai casi di bronchiolite cronica.

### References

- Ahlstedt S. and Enander I.*: Immune regulation of goblet cell development. *Int. Archs. Allergy appl. Immun.* 82, 357–360 (1987). – *Anon.*: Understanding equine pulmonary disease. *Vet. Rec.* 117, 141 (1985). – *Bang B.G. and Bang F.B.*: Responses of the upper respiratory mucosa to dehydration and infection. *Ann. New York Acad. Sci.* 106, 625–630 (1963). – *Cochrane C.G.*: Immunologic tissue injury mediated by neutrophilic leukocytes. *Adv. Immunol.* 102, 97–162 (1968). – *Cook W.R.*: Chronic bronchitis and alveolar emphysema in the horse. *Vet. Rec.* 99, 448–451 (1976). – *Cook W.R. and Rossdale P.D.*: The syndrome of «broken wind» in the horse. *Proc. Royal Soc. Med.* 56, 972–977 (1963). – *Dungworth D.L.*: The respiratory system. In: *Pathology of Domestic Animals*. Vol. 2, K.V.F. Jubb, P.C. Kennedy and N. Palmer (eds.), 3rd ed., Academic Press, Inc., pp. 413–557 (1985). – *Eyre P.*: Equine pulmonary emphysema: a bronchopulmonary mold allergy. *Vet. Rec.* 91, 134–140 (1972). – *Falk H.L., Kotin P. and Rowlette W.*: The response of mucus secreting epithelium and mucus to irritants. *Ann. New York Acad. Sci.* 106, 583–608 (1963). – *Gerber H.*: Klinik und Therapie chronischer Lungenleiden des Pferdes. *Dtsch. Tierärztl. Wsch.* 76, 234–239 (1969). – *Gerber H.*: Chronic pulmonary disease in the horse. *Eq. Vet. J.* 5, 26–33 (1973). – *Gillespie J.R. and Tyler W.S.*: Clinical alveolar emphysema in the horse. *Adv. Vet. Sci.* 13, 59–99 (1969). – *Grünig G., Hermann M., Jorisch S., Shaerer C. and von Fellenberg R.*: Proteaseaktivität im Tracheobronchialsekret von Pferden mit COPD: Pathophysiologische Bedeutung. *Pferdeheilkunde* 1, 55–63 (1985). – *Johnson K.J. and Ward P.A.*: Role of oxygen metabolites in immune complex injury of lung. *J. Immunol.* 126, 2365–2369 (1981). – *Lazary S., Gerber H., Friedrich W., Schatzmann U., Straub R., De Weck A.L. and Rivera E.*: Hypersensitivity in the horse with special reference to reaction in the lung. *Proc. III Int. Conf. Eq. Inf. Diseases*, Paris, pp. 501–508 (1973). – *Lowell F.C.*: Observations on «heaves» – an asthma-like syndrome in the horse. *J. Allergy* 35, 322–330 (1964). – *Mirbahar K.B. and Eyre P.*: Chronic obstructive pulmonary disease (COPD) in horses. *Vet. Ann.* 26, 146–155 (1986). – *McPherson E.A., Lawson G.H.K., Murphy J.R., Nicholson J.M., Breeze R.G. and Pirie H.M.*: Chronic obstructive pulmonary disease (COPD) in horses: Aetiological studies: Responses to intradermal and inhalation antigenic challenge. *Eq. Vet. J.* 11, 159–166 (1979). – *Muyelle E., Vanden Hende C. and Oyaert W.*: Nitrogen clearance in horses as a respiratory function test. *Zbl. Vet. Med. A* 19, 310–317 (1972). – *Pascoe J.R., Ferraro G.L., Cannon J.H., Arthur R.M. and Wheat J.D.*: Exercise-induced pulmonary hemorrhage in racing thoroughbreds: A preliminary study. *Am. J. Vet. Res.* 42, 703–707 (1981). – *Pascoe J.R., O'Callaghan M.W., Tyler W.S. and Mason D.K.*: Exercise-induced pulmonary hemorrhage – an update. *Proc. 32nd. Ann. Conv. Am. Ass. Eq. Pract.* 263–267 (1986). – *Schatzmann U., Straub R., Gerber H., Lazary S., Meister U. and Spörri H.*: Die Elimination von Heu und Stroh als Therapie chronischer Lungenerkrankungen des Pferdes. *Tierärztl. Prax.* 2, 207–214 (1974). – *Schoon H.A. and Deegen E.*: Histopathologie der chronisch obstruktiven Bronchitis bei klinisch manifest erkrankten Pferden. *Tierärztl. Prax.* 11, 213–221 (1983). – *Thorsen J., Willoughby R.A., McDonell W., Valli V.E.O., Viel L. and Bignell W.*: Influenza hemagglutination inhibiting activity in respiratory mucus from horses with chronic obstructive pulmonary disorders (heaves syndrome). *Can. J. Comp. Med.* 47, 332–335 (1983). – *Viel L.*: Structural-functional correlations of the lung in horses with small airway disease. PhD Thesis, University of Guelph, Canada (1983). – *Winder N.C. and von Fellenberg R.*: Immunofluorescent evaluation of the lower respiratory tract of healthy horses and of horses with chronic bronchiolitis. *Am. J. Vet. Res.* 47, 1271–1274 (1986). – *Winder N.C.*: Chronic small airway disease in the horse: Pathologic and immunohistochemical studies. Inaugural Dissertation, University of Zurich, Switzerland (1987).

### Acknowledgements

The authors gratefully acknowledge the advice of Dr. F. Ehrensperger, the technical assistance of Mrs. R. Weilenmann and co-workers and the photographic assistance of Mrs. A. Hug. This research was supported by grant No. 3.877-0.83 from the Swiss National Science Foundation.

Registration of the manuscript: July 14th 1987

## PERSONELLES

### Professor Dr. Herbert Jucker zum 70. Geburtstag



Am 3. November konnte Professor Jucker im Kreise seiner Familie den 70. Geburtstag feiern. Herbert Jucker wurde als Bauernsohn in Dettenried-Weisslingen im Zürcher Oberland geboren. 1937 bestand er die Matura an der Kantonsschule Winterthur. Sein Studium an der Abteilung für Landwirtschaft der ETH Zürich schloss er 1942 mit dem Diplom als Ingenieur-Agronom ab. Bis 1946 war er Assistent am Institut für Haustiernahrung bei Prof. Dr. E. Crasemann. Auch als wissenschaftlicher Mitarbeiter der Holzverzuckerungs-AG Ems und später der Genossenschaft UFA blieb er an diesem Institut der ETHZ. Seine 1948 erschienene Dissertation trägt den Titel «Die Wirkung reiner Kartoffelstärke auf den Fettansatz beim ausgewachsenen Schaf» und

war ein Beitrag zur energetischen Bewertung der Futtermittel nach Oskar Kellner.

Während seiner langjährigen Tätigkeit am Institut für Haustiernahrung hielt Dr. Jucker ab und zu stellvertretend für Prof. Crasemann an der veterinärmedizinischen Fakultät Vorlesungen über Tierernährung. So fiel die Wahl nicht schwer, als es darum ging, «an der veterinärmedizinischen Fakultät in Zürich einen Spezialisten zur Verfügung zu haben, welcher sich mit allen für den Tierarzt wesentlichen Fragen der Tierernährung befassen kann» (aus dem Antrag der Fakultät vom 21. September 1965 an die Erziehungsdirektion des Kantons Zürich). Auf Beginn des Sommersemesters 1966 wurde Dr. H. Jucker zum Assistenzprofessor ernannt. Er war damit der erste Dozent an unseren beiden Fakultäten, der sich einzig mit dem bedeutenden Gebiet der Tierernährung befasste.

Die Abteilung für Tierernährung war vorerst Teil des Tierzucht-Instituts und wurde 1972 als Abteilung für Physiologie und Pathophysiologie der Tierernährung dem Veterinär-Physiologischen Institut eingegliedert. Auf Beginn des Wintersemesters 1973/74 wurde Professor Jucker zum Extraordinarius befördert.