

Zeitschrift: Schweizer Archiv für Tierheilkunde SAT : die Fachzeitschrift für Tierärztinnen und Tierärzte = Archives Suisses de Médecine Vétérinaire ASMV : la revue professionnelle des vétérinaires

Band: 132 (1990)

Heft: 8

Artikel: Intravascular macrophages in the lung of rabbits with experimental viral haemorrhagic disease

Autor: Carrasco, L. / Gómez-Villamandos, J.C. / Díaz, E.

DOI: <https://doi.org/10.5169/seals-593014>

Nutzungsbedingungen

Die ETH-Bibliothek ist die Anbieterin der digitalisierten Zeitschriften. Sie besitzt keine Urheberrechte an den Zeitschriften und ist nicht verantwortlich für deren Inhalte. Die Rechte liegen in der Regel bei den Herausgebern beziehungsweise den externen Rechteinhabern. [Siehe Rechtliche Hinweise.](#)

Conditions d'utilisation

L'ETH Library est le fournisseur des revues numérisées. Elle ne détient aucun droit d'auteur sur les revues et n'est pas responsable de leur contenu. En règle générale, les droits sont détenus par les éditeurs ou les détenteurs de droits externes. [Voir Informations légales.](#)

Terms of use

The ETH Library is the provider of the digitised journals. It does not own any copyrights to the journals and is not responsible for their content. The rights usually lie with the publishers or the external rights holders. [See Legal notice.](#)

Download PDF: 06.10.2024

ETH-Bibliothek Zürich, E-Periodica, <https://www.e-periodica.ch>

not consistently seen, but granulomas generally associated with trophozoites in glomeruli of some puppies were noted. The light-microscopic findings were supported by electron-microscopic findings of amebic trophozoites in brain and lung samples. Direct immunofluorescence performed at the Centers for Disease Control in Atlanta, Georgia, on lung and brain samples identified the amebic organisms to belong to the genus *Acanthamoeba*. *Acanthamoeba* provide a

diagnostic challenge in that they are difficult to differentiate from certain mammalian cells, especially macrophages. The diagnostic feature of *Acanthamoeba* in histopathologic sections is the central nucleolus. Specific laboratory procedures are generally necessary to confirm *Acanthamoeba* infection.

Dpto. Anatomía y Anatomía Patológica, Córdoba, Spain

INTRAVASCULAR MACROPHAGES IN THE LUNG OF RABBITS WITH EXPERIMENTAL VIRAL HAEMORRHAGIC DISEASE

L. Carrasco, J. C. Gómez-Villamandos, E. Díaz, J. B. Poveda, A. Fernández

The haemorrhagic viral disease (HVD) occurring in rabbits is characterized by severe necrotic hepatitis and congestive-haemorrhagic phenomena affecting different organs including the lungs (4). It is usually diagnosed on liver and lung samples, which usually show the highest viral titres in the affected animals (4).

Pulmonary intravascular macrophages (PIMs) are elements of the mononuclear phagocytic system (MPS) reported to occur in the lumina of pulmonary capillaries and arterioles in pigs, ruminants and felines (4-6, 8, 9).

The presence of PIMs endow the animals concerned with special features, both at the pulmonary and at the general level, which have been investigated by several authors; their occurrence has been related to the most common hydrodynamic pulmonary changes found in the species possessing them (2, 8, 9).

Six rabbits free from infectious and parasitic diseases were orally and parenterally inoculated with liver tissue extract from animals suffering from natural HVD and diagnosed by haemagglutination and electron microscopy.

Two days after inoculation, the animals were sacrificed after anaesthetization with ether by vascular perfusion with 2% glutaraldehyde in phosphate buffer; once perfused, 1-mm³ samples from the cranial, medial and caudal lobes were collected and fixed in the same medium, after which they were refixed in 2% osmium tetroxide and embedded in Durcupam ACM. 50-nm sections were stained with uranyl acetate and lead citrate, and then studied under a Philips CM-10 microscope at the Electron Microscopy Service of the University of Córdoba.

Bacterial clearance in rabbits reportedly occurs chiefly in the liver, spleen and marrow. However, some rabbits have been reported to undergo migration of Kupffer cells to the lungs on injection of colloid substances; this has also been reported to occur in cats on thorax ventilation, cells being later identified as PIMs (6).

The macrophages occurring in the alveolar capillaries of the inoculated rabbits showed the morphological features of PIMs reported by many authors (2, 7-9), namely uneven morphology, occurrence of pseudopodes and phagosomes, closeness to the vascular endothelium and, occasionally, linking modes to these cells.

Pulmonary intravascular erythrophagocytosis has been reported to occur in species with PIMs (1, 5, 7, 9), as has granulocyte phagocy-

tosis on inoculation of bacteria (2), endotoxins (8) and viruses (7); according to some authors (2, 7-9), these cells play a major role in lung clearance. According to our own experience, most PIMs show

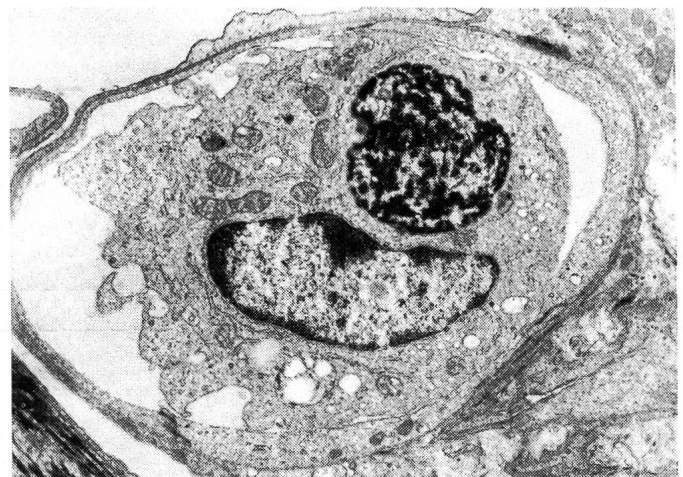

Fig. 1: Pulmonary intravascular macrophage with secondary lysosomes. X 15 000.

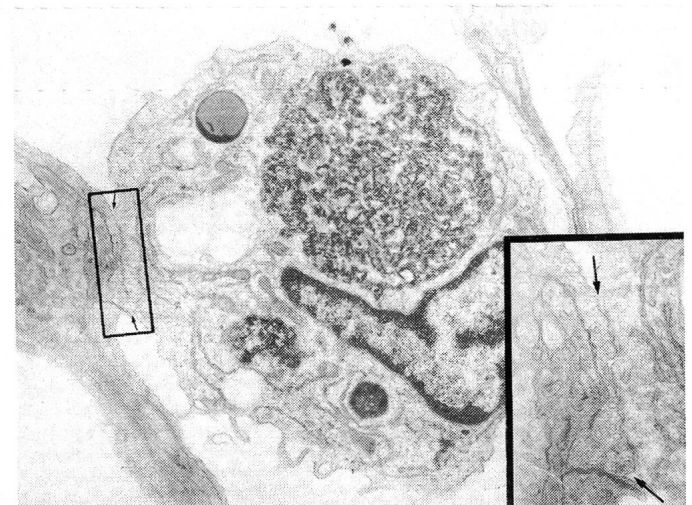

Fig. 2: Pulmonary intravascular macrophage. X15000. Insert: Intercellular junction of a pulmonary intravascular macrophage.

phagosomes consisting of cell debris and/or erythrocytes, as well as electron-dense structures of 20–30 nm diameter resembling the HVD virus particles.

Phagocytosis stimulation normally leads to intravascular macrophage expansion (9), which might be related to the loss of the flattened appearance of these cells in healthy animals (9). Such a loss has also been reported to occur on inoculation of endotoxin (8) and the African swine fever virus (7); in this last case, and because of the cytopathic effect of the virus on the macrophages, where it replicates, they undergo some rounding and show few linking modes, which is consistent with the image of most of the macrophages observed by us, where replication did not seem to occur.

Most authors (2, 7–9) relate the phagocytosis of blood forming elements and cell debris to hydrodynamic pulmonary changes which may arise from the expansion of the macrophages, with the resulting

increase in capillary resistance and contribution to pulmonary hypertension and edema, the last of which is reportedly one of the major features of HVD.

References

1. Atwal O. S., Saldanha K. A. (1985): *Acta Anat.* 124, 245–254. —
2. Bertram T. A. (1986): *Vet. Pathol.* 23, 681–691. —
3. Crocker S. H. et al. (1981): *Surgery, Gynecology, Obstetrics* 153, 845–851. —
4. Liu S. J. et al. (1984): *An Husbandry, Vet. Med.* 16, 253–255. —
5. Rybicka K. et al. (1974): *Am. J. Anat.* 139, 353–368. —
6. Schneeberger-Keely E. E., Burger E. J. (1970): *Lab. Invest.* 22, 361–369. —
7. Siarra M. A. et al. (1990): *J. Comp. Path.* 102. —
8. Warnes A. E. et al. (1988): *Lab. Invest.* 59, 219–229. —
9. Winkler G. C. (1988): *Am. J. Anat.* 181, 217–234.

Dep. Anim. Pathology, School of Vet. Medicine, Torino, Italy

ELECTRON MICROSCOPIC OBSERVATIONS ON ATRIAL MYOENDOCRINE CARDIAC CELLS IN BOVINE, PIG AND RABBIT HEART TISSUE

M. Castagnaro, M. Negro, F. Guarda

Adult mammalian atrial myocardium contains a cell population characterized by the presence of electron dense membrane-bound granules referred as atrial specific granules.¹

Immunohistochemical studies at light and electron microscopic levels carried out in man and rat, showed that these granules contain bioactive polypeptides, referred as Atrial Natriuretic Peptide (ANP) or Atrial Natriuretic Factor (ANF), involved in water-electrolyte

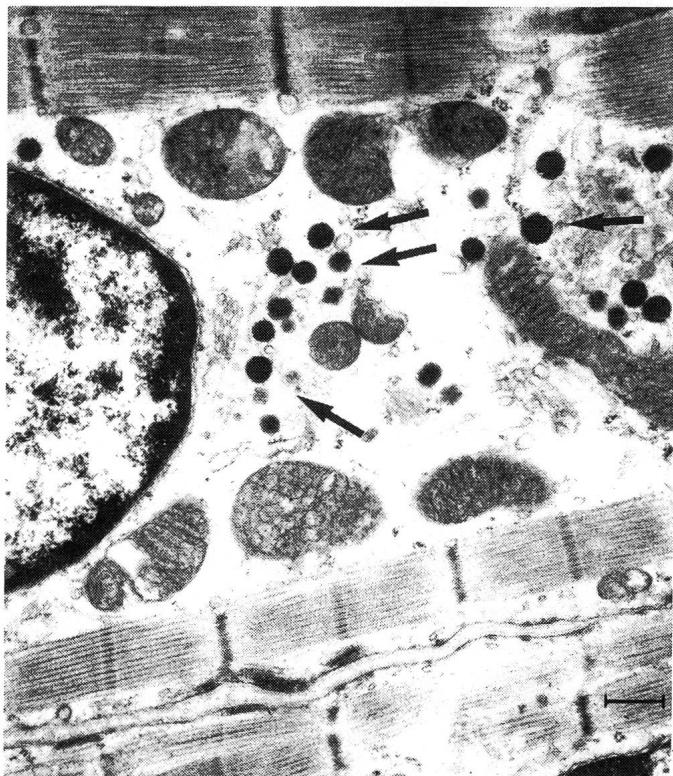

Fig. 1: Electron micrograph, left auricle, rabbit. Atrial specific granules (arrows) are typically found at the nuclear poles. Bar = 0.40 μ m.

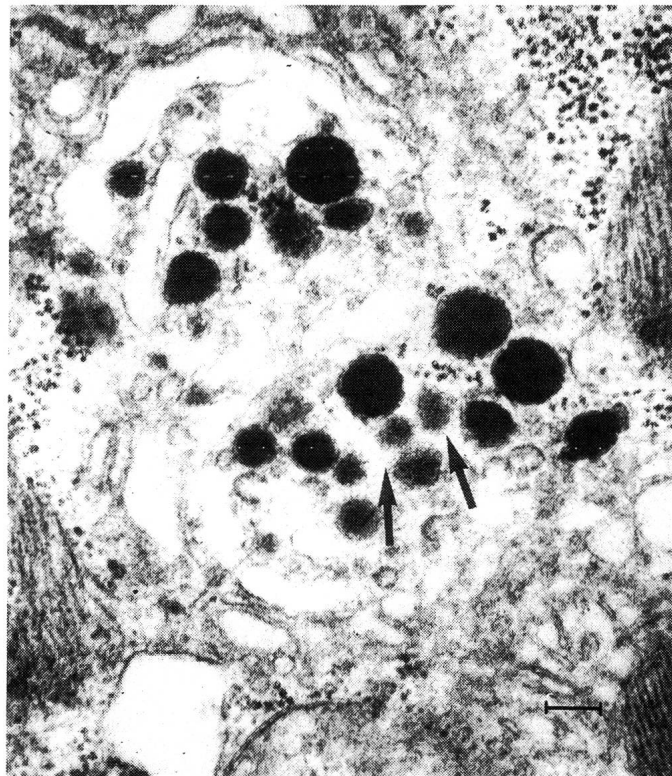


Fig. 2: Electron micrograph, right auricle, cow. Some progranules (arrows) are present in the Golgi cisternae. Other mature granules can also be observed. Bar = 0.15 μ m.