

Zeitschrift: Schweizer Archiv für Tierheilkunde SAT : die Fachzeitschrift für Tierärztinnen und Tierärzte = Archives Suisses de Médecine Vétérinaire ASMV : la revue professionnelle des vétérinaires

Band: 132 (1990)

Heft: 8

Artikel: Immunohistological study on kidneys from dogs with spontaneous leishmaniasis

Autor: Castaño, M. / Gomez, M. / Peña, L.

DOI: <https://doi.org/10.5169/seals-593242>

Nutzungsbedingungen

Die ETH-Bibliothek ist die Anbieterin der digitalisierten Zeitschriften. Sie besitzt keine Urheberrechte an den Zeitschriften und ist nicht verantwortlich für deren Inhalte. Die Rechte liegen in der Regel bei den Herausgebern beziehungsweise den externen Rechteinhabern. [Siehe Rechtliche Hinweise.](#)

Conditions d'utilisation

L'ETH Library est le fournisseur des revues numérisées. Elle ne détient aucun droit d'auteur sur les revues et n'est pas responsable de leur contenu. En règle générale, les droits sont détenus par les éditeurs ou les détenteurs de droits externes. [Voir Informations légales.](#)

Terms of use

The ETH Library is the provider of the digitised journals. It does not own any copyrights to the journals and is not responsible for their content. The rights usually lie with the publishers or the external rights holders. [See Legal notice.](#)

Download PDF: 06.10.2024

ETH-Bibliothek Zürich, E-Periodica, <https://www.e-periodica.ch>

spermatogonia in normal testis stained any cells in seminomas. These data suggest that seminomas do not contain spermatogonia. Furthermore, except SBA-N, which reacted only with two seminomas, none of the lectins that bound to postmeiotic spermatogenic cells in the normal testis reacted with any cells in seminoma.

Finally, RCA-II and LCA did not stain Sertoli cell tumours even though they bind to Sertoli cells in normal conditions. These preliminary results suggest that lectin histochemistry may be useful for the differential diagnosis of neoplastic lesions of dog testicle. However, further studies on a higher number of cases and on tumours with

intermediate differentiation and/or in combined tumours with different degrees of intermingling of cells are needed to confirm our observations.

References

1. Arya M., Vahna-Perttula T. (1986): *Am. J. Anat.*, 175, 449-469.
- 2. Lee M.-C., Damjanov I. (1985): *Anat. Rec.*, 212, 282-287.
3. Teshima S. et al. (1984): *Lab. Invest.*, 50, 271-277.
- 4. Malmi R., Soderstrom K.-O. (1985): *Virch., Arch. A*, 413, 69-75.
- 5. Lee M.-C. (1985): *Arch. Pathol. Lab. Med.*, 109, 938-942.

D^o de Patologia Animal Fac. de Veterinaria. Universidad Complutense de Madrid, Spain

IMMUNOHISTOLOGICAL STUDY ON KIDNEYS FROM DOGS WITH SPONTANEOUS LEISHMANIASIS

M. Castaño, M. Gomez, L. Peña, J. M. Flores, M. Gonzalez

The canine leishmaniasis is an endemic disease in the Mediterranean area. In our department we receive numerous patients, that are, most of them, sacrificed.

From the decade of the 70's on we began the study on the renal lesions as this organ is one of the most affected by the disease, according to Millin et al. (1975), Castaño et al. (1981) and Poli et al. (1989).

Most of the authors (Poli et al., 1986; Castano et al., 1988; Pizarini (1989), say that the most frequent lesion observed is a membranoproliferative glomerulonephritis (MPGN).

We would like to study the pathogenesis of the process and analyze the possible relationship between the glomerular lesions and the deposits of IgG, IgA, IgM and C₃ in leishmaniasis.

Material and methods

We used 16 dogs between 3 and 6 years old, positive 1/400 with IFI techniques.

Once the necropsies were carried out, the renal samples were fixed in 10% formalin and Bouin's solution and embedded in paraffin and methacrylate. The samples were stained with H-E, PAS, Silver methenamine and PAP methods. Anticanine IgG, IgA, IgM and C₃ were used. We carried positive and negative controls.

For the ultrastructural study the tissues were fixed in 3% Milloning-buffered glutaraldehyde, pH 7.3 and post-fixed in 1% osmium tetroxide, embedded in epon-araldite and stained with lead citrate and uranyl acetate.

Results and discussion

We divided the different forms of glomerulonephritis into 4 types: Minimal changes, MPGN focal and segmental, MPGN type I and MPGN type II; they were represented in proportions of 12%, 24%, 42% and 22% respectively. (Fig. 1)

Kidneys of the dogs with minimal changes had very little morphological modifications, we only observed a small increase of the mesangial area. In this case we detected glomerular deposits of IgM and C₃ of medium degree; they were negative for IgA and IgM, like Churg and Sobin (1982) observed.

The MPGN focal and segmental was characterized by a partial increase of the mesangial area and hypertrophy of the basement

membranes. In the immunohistological studies we observed intramembranous deposits of IgG and C₃. In the chronic process IgM

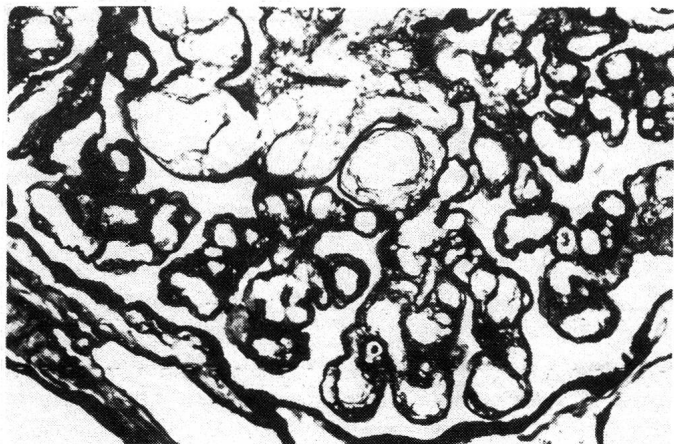


Fig. 1: MPGN type I. Double contour of basement membrane. Silver Methenamine. 40X.

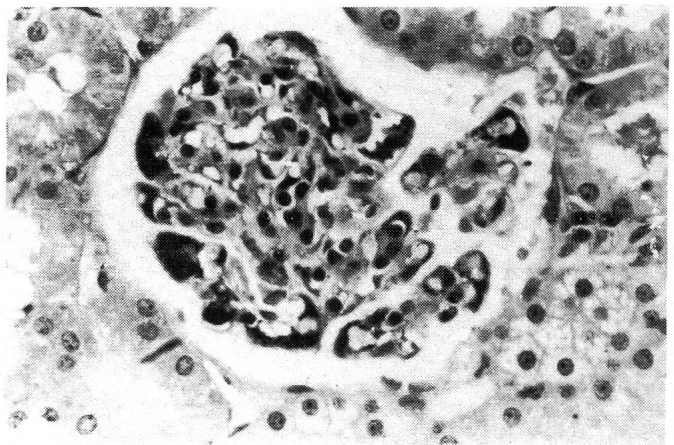


Fig. 2: MPGN: Heavy deposits of IgM. PAP Method. 25x.

deposits appeared in the membrane and mesangial area. These results are similar to the ones observed by Pizzirani (1989).

In the cases of MPGN types I and II we saw immunocomplex deposits in the subendothelial area in the type I and in subepithelial and mesangial areas in the type II.

We observed important immunological differences between these two types. In the MPGN type I we found deposits of IgG, IgA, IgM and C₃ and in the MPGN type II we principally found IgM (Fig. 2) and a smaller proportion of C₃. These results correspond with the observations of Rosen (1983).

In conclusion, the results of this study indicate that immunologically the deposits are IgG and C₃ in the initial lesions and IgG and C₃ in

the advanced stages of glomerulonephritis and glomerular sclerosis. IgA did not appear to play a role in the process.

References

1. Castaño M., Gonzalez J. L. (1981): Proc. 1° Congreso Latinomediterraneo Med. Vet. Pic. anim. 9. — 2. Castaño M., Flores J. M., Novoa C., Gonzalez M. (1988): Proc. 9th Autumn meeting. San Remo, Italy. 20. — 3. Churg J., Sobin L. H. (1982): Igaku-Shoin. Tokyo. New York. — 4. Pizzirani S. (1989): SCIVAC. II Convegno sulla Leishmaniosi. Pugnochiuso. — 5. Poli A. et al. (1988): Proc. 9th Autumn meet. San Remo, Italy. 19. — 6. Rosen, M. D. (1983): Churchill Livingstone Inc. New York.

Institut für Tierpathologie, Ludwig-Maximilians-Universität, München

IDENTIFICATION OF CANINE AND FELINE MEGAKARYOCYTIC CELLS (NORMAL/LEUKEMIC) BY THE DEMONSTRATION OF GLYCOPROTEIN GPIIB/IIIA AND VON WILLEBRAND FACTOR

F. Colbatzky, J. Darbès, G. Minkus, W. Hermanns

It is nearly impossible to discern the immature blast cells of the four hematopoietic cell lines in paraffin sections routinely stained with hematoxylin-eosin or Giemsa. So the reliable identification of promegakaryoblasts and megakaryoblasts is difficult. Besides, some tumours such as myelomas or osteoclastomas can show morphologic characteristics very similar to those of megakaryocytic leukemia.

We, therefore, used air-dried blood films from EDTA-anticoagulated blood, glass slides with platelet films prepared by centrifugation of platelet-rich plasma in a special cytocentrifuge, and cryostat, paraffin as well as plastic sections of normal bone marrow to develop a method for the immunohistochemical demonstration of normal and leukemic megakaryocytic cells in formalin-fixed tissue samples in dogs and cats. In addition, formalin-fixed and paraffin or plastic embedded organ specimens of one cat and two dogs suffering from megakaryocytic leukemia were investigated. The 3 monoclonal antibodies Y2/51 (Dakopatts), CLB-37 (Janssen) and HPL-1 (Sera-Lab) directed against antigenic determinants on the human glycoprotein complex gpIIb/IIIa and a polyclonal antiserum directed against human von Willebrand factor (anti-vWF, Dakopatts) were used.

According to our hitherto performed investigations strong and reliable immunohistochemical staining of normal and leukemic mega-

karyocytic cells could only be achieved with Y2/51 and anti-vWF in paraffin sections. Plastic sections always gave negative results with all antibodies used. The monoclonal antibody CLB-37 detected only human and feline platelets and megakaryocytic cells. The intensity of reaction products was always considerably lower in dogs than in cats. In both species the results with anti-vWF were generally better than with the monoclonal antibodies. In the three cases of megakaryocytic leukemia both megakaryocytes and blast-like tumour cells were stained, the number of positive tumour cells being higher in the cat. All three cases showed a strong labeling of endothelial cells with anti-vWF.

To test the specificity of the monoclonal antibodies in dogs and cats, probes of platelet membranes were prepared for SDS-PAGE. The electrophoretically separated proteins were then blotted to nitrocellulose filters and stained by an indirect immunoperoxidase technique. In both species the monoclonal antibody Y2/51 detected a protein, which was in respect of the molecular weight similar to human gpIIIa (unreducing conditions). As expected, HPL-1, which is directed against the whole glycoprotein complex gpIIb/IIIa, gave negative results. Similarly, the binding site of the gpIIIa specific monoclonal antibody CLB-37 was obviously destroyed in the experimental conditions.

Laboratoire d'anatomie pathologique, INRA, Alfort cedex

DEMONSTRATION BY IMMUNOCYTOCHEMICAL METHODS OF THE T LYMPHOCYTIC ORIGIN OF A FAMILIAL BOVINE THYMIC LYMPHOSARCOMA

B. Da Costa, S. Djilali, B. Sacré, J. L. Kessler, F. Femenia, A. L. Parodi

Bovine leukosis is a malignant tumour of lymphoid cells. Four epidemiological and anatomical forms of the disease are known: the adult multicentric form, the cutaneous form, the adolescent thymic form and the multicentric calf form (Bendixen, 1965) (1).

The observation of 216 cases of the thymic form of bovine leukosis during a short period in some areas of France prompted us to

undertake studies of these unusual tumours. A genetic survey demonstrated that all the leukotic calves were sired by the same bull. The occurrence has been estimated to 3% among the offspring of the bull (2).

Material and methods

A complete study was undertaken in 38 tumour cases by hematology, serology, light and electronic microscopy and immunocytochemi-