

# A simple procedure for the gross and histological examination of the bovine hoof

Autor(en): **Ossent, P.**

Objekttyp: **Article**

Zeitschrift: **Schweizer Archiv für Tierheilkunde SAT : die Fachzeitschrift für Tierärztinnen und Tierärzte = Archives Suisses de Médecine Vétérinaire ASMV : la revue professionnelle des vétérinaires**

Band (Jahr): **132 (1990)**

Heft 8

PDF erstellt am: **21.07.2024**

Persistenter Link: <https://doi.org/10.5169/seals-593657>

## **Nutzungsbedingungen**

Die ETH-Bibliothek ist Anbieterin der digitalisierten Zeitschriften. Sie besitzt keine Urheberrechte an den Inhalten der Zeitschriften. Die Rechte liegen in der Regel bei den Herausgebern.

Die auf der Plattform e-periodica veröffentlichten Dokumente stehen für nicht-kommerzielle Zwecke in Lehre und Forschung sowie für die private Nutzung frei zur Verfügung. Einzelne Dateien oder Ausdrucke aus diesem Angebot können zusammen mit diesen Nutzungsbedingungen und den korrekten Herkunftsbezeichnungen weitergegeben werden.

Das Veröffentlichen von Bildern in Print- und Online-Publikationen ist nur mit vorheriger Genehmigung der Rechteinhaber erlaubt. Die systematische Speicherung von Teilen des elektronischen Angebots auf anderen Servern bedarf ebenfalls des schriftlichen Einverständnisses der Rechteinhaber.

## **Haftungsausschluss**

Alle Angaben erfolgen ohne Gewähr für Vollständigkeit oder Richtigkeit. Es wird keine Haftung übernommen für Schäden durch die Verwendung von Informationen aus diesem Online-Angebot oder durch das Fehlen von Informationen. Dies gilt auch für Inhalte Dritter, die über dieses Angebot zugänglich sind.

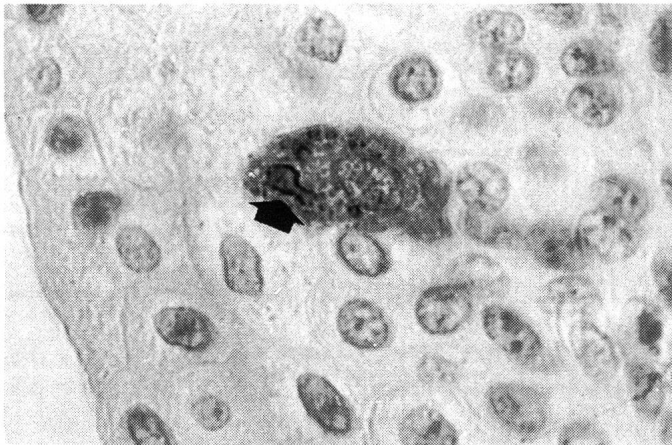


Fig. 2: Urinary bladder. Peroxidase positive material and inclusion bodies (arrow) in the transitional epithelium. IPI. X600

by immunohistochemical methods (5, 8, 9). Such inclusions may represent residual cellular matrix or herpes simplex inclusions (6). Immunocytochemical techniques have been used for the demonstration of DV antigen in tissues of dogs (5, 8, 9) and minks (3). The detection of positive reacting tissues, using a monoclonal antibody against canine DV in foxes, suggested that the same agent is the cause of the infection or that DV in foxes shows cross-reactivity. The detection of positive reacting tissues that were negative for inclusion bodies was also reported in dogs (5) and can be explained by the late

appearance of inclusion bodies or by the decrease of these inclusions 15-20 days post infectionem (6).

Respiratory, lymphoid and urinary organs were positive to the detection of DV antigen in the present study. No lesions or positive reaction were found in the nervous system.

By electron-microscopic studies we have demonstrated intracytoplasmic DV-like particles in the epithelium of renal pelvis. This technique provides the evidence of distemper infection but it is time-consuming and needs a special procedure not always available in a diagnostic histopathological laboratory.

In conclusion, distemper infection in foxes could be proved efficiently by the combination of histopathology and immunohistochemistry. The immuno peroxidase procedure is more efficient and specific than the evidence of inclusion bodies.

### References

1. Appel MJC. (1969): Am. J. Vet. Res. 130, 1167-1182. — 2. Appel MJG et al. (1981): In: Kurstak, E; Kurstak, C, eds. Comparative diagnosis of viral diseases. Vol. 4. Academic Press Inc., 235-297. — 3. Blixenkronne M. (1989): Am. Jf. Vet. Res. 50, 1616-1620. — 4. Cornwell HJC. et al. (1965): J. Comp. Pathol. 75, 3-17. — 5. Ducatelle R. et al. (1980): Am. J. Vet. Res. 41, 1860-1862. — 6. Fairchild GA. et al. (1967): Am. J. Vet. Res. 28, 761-768. — 7. Krakowka S. et al. (1985): In: Olsen, RG; Krakowka, S; Blakeslee, J. R., eds. Comparative pathobiology of viral diseases. Vol. 2. Boca Raton, Fla: CRC Press Inc. 138-164. — 8. Myry C. et al. (1983): Res. Vet. Sci. 34, 145-148. — 9. Nieto J. M. et al. (1987): Med. Vet. 4, 29-33. — 10. Orvell C. et al. (1985): J. Gen. Virol. 66, 443-456.

*Institute of Veterinary Pathology, University of Zurich, Switzerland*

### A SIMPLE PROCEDURE FOR THE GROSS AND HISTOLOGICAL EXAMINATION OF THE BOVINE HOOF.

*P. Ossent*

The method is based simply on the removal of the whole horn shoe. In spite of its simplicity and efficiency, and although every pig undergoes essentially the same process at slaughter, the technique has hardly been used for the examination of bovine claws. Nilsson (1) and Maclean (2), in the early 1960's, exungulated bovine claws but apparently did not make use of hot water, which greatly reduces artifact. The usual procedure for the inspection of the inner regions of the claw at routine necropsy as well as in the literature is simply to saw a sagittal section of the hoof. In the bovine, this delivers nearly no information.

First, the foot is cleaned and the solar surface of the claw is pared to expose any haemorrhages or defects. Next, the foot is immersed to the level of the coronary band in hot water for several minutes until the inner temperature reaches approx. 60°C. The horn shoe is then removed with the help of a vice.

The exposure of the complete surface of the corium and the inner surface of the horn shoe presents a correspondingly complete picture of the situation. It allows specific tissue sampling for histology from

e.g. focal lesions which is otherwise impossible. The line of separation between shoe and its substrate is usually in the str. spinosum, so the transitional zone may be studied microscopically. The deeper layers of the dermis and the surface of the claw bone are easily accessible, as is the bone itself which may be macerated and cleaned to expose any defects at that level too.

Indeed, the method's application is not restricted to the necropsy room. The simplicity of the method allows it to be carried out on the farm yard. This may be indicated in slaughtered animals with e.g. acute and subacute laminitis, where a marked discrepancy between the lack of visible changes in the live animal and the very pronounced interior lesions is common. The practitioner may demonstrate the severity of the lesions to the owner and thus remove any possible vestiges of doubt that the decision to slaughter the cow was justified.

### References

1. Nilsson SA. (1963): Acta Vet. Scand. 4, Suppl. 1, 1-304. — 2. Maclean CW. (1965): Vet. Rec. 77, 662-672.