

**Zeitschrift:** Schweizer Archiv für Tierheilkunde SAT : die Fachzeitschrift für Tierärztinnen und Tierärzte = Archives Suisses de Médecine Vétérinaire  
ASMV : la revue professionnelle des vétérinaires

**Herausgeber:** Gesellschaft Schweizer Tierärztinnen und Tierärzte

**Band:** 139 (1997)

**Heft:** 10

**Artikel:** Feline Poxvirus Infection : a case report

**Autor:** Canese, M.G. / Lavazza, A. / Massone, A.

**DOI:** <https://doi.org/10.5169/seals-592994>

### **Nutzungsbedingungen**

Die ETH-Bibliothek ist die Anbieterin der digitalisierten Zeitschriften. Sie besitzt keine Urheberrechte an den Zeitschriften und ist nicht verantwortlich für deren Inhalte. Die Rechte liegen in der Regel bei den Herausgebern beziehungsweise den externen Rechteinhabern. [Siehe Rechtliche Hinweise.](#)

### **Conditions d'utilisation**

L'ETH Library est le fournisseur des revues numérisées. Elle ne détient aucun droit d'auteur sur les revues et n'est pas responsable de leur contenu. En règle générale, les droits sont détenus par les éditeurs ou les détenteurs de droits externes. [Voir Informations légales.](#)

### **Terms of use**

The ETH Library is the provider of the digitised journals. It does not own any copyrights to the journals and is not responsible for their content. The rights usually lie with the publishers or the external rights holders. [See Legal notice.](#)

**Download PDF:** 06.02.2025

**ETH-Bibliothek Zürich, E-Periodica, <https://www.e-periodica.ch>**

# Feline Poxvirus Infection. A case report

M. G. Canese<sup>1</sup>, A. Lavazza<sup>2</sup>, A. Massone<sup>2</sup>, F. Galeano, M. Boldini<sup>2</sup>

## Summary

Poxvirus infection of a domestic cat is reported. The clinical signs consisted of skin lesions only, which healed within two and a half months. Histopathology revealed cytoplasmatic inclusion bodies typical of pox virus infection. Virus particles morphologically related to the genus orthopoxvirus were detectable in the embedded skin tissue and in skin scraping by electron microscopy. No specific lesions were observed in the chick embryo chorioallantoic membrane inoculated with an extraction from skin scabs of the cat.

**Key words:** poxvirus – cat – viral isolation – histopathology – ultrastructure

## Infezione da pox virus nel gatto. Descrizione di un caso

È riportato un caso di infezione da Poxvirus in un gatto. Il quadro clinico era caratterizzato esclusivamente da lesioni cutanee e la malattia si è risolta nell'arco di tempo di due mesi e mezzo. L'osservazione istopatologica consentiva di rilevare la presenza di corpi inclusi citoplasmatici nelle cellule dell'epidermide, tipici dell'infezione da poxvirus. L'indagine ultrastrutturale ha permesso di identificare particelle virali, riferibili ad ortopoxvirus, sia su sezioni di tessuto cutaneo, sia nell'estratto da ulcere cutanee. Quest'ultimo però non ha indotto lesioni specifiche nelle membrane corioallantoiche di embrione di pollo.

## Introduction

Feline poxvirus infection was first detected in a cheetah and in a domestic cat (Thomsett et al., 1978; Baxbay et al., 1979), and further cases in both animals were seen the following year (Baxbay et al., 1982; Gaskell et al., 1983; Martland et al., 1983; Hoare et al., 1984; Webster and Jefferies 1984; Bennett et al., 1985). The cat is now the most frequently recognised host of cowpox virus and several reports have described the clinical and epidemiological features of the natural disease (Gaskell et al., 1983; Hoare et al., 1984; Martland et al., 1985; Bennett et al., 1985; 1986) and the experimental infection (Gaskell et al., 1983; Bennett et al., 1989).

Affected animals show multiple skin lesions which usually heal, although some cats develop more severe or fatal systemic illness (Martland et al., 1985; Hoare and Bennett, 1985; Bennett et al., 1989).

We report here the first case of feline poxvirus infection reported in Italy.

## Animal, materials and methods

### Clinical history

A two-month-old European male cat was presented with two ulcerated areas of the skin on the right ear. The cat also suffered from bacterial otitis in the same ear. It was heavily infested with ascarids and coccidia and it was FIV and FIP seronegative.

Skin lesions, apparently due to scratching, rapidly spread to affect the head a few days later. A tentative diagnosis of allergic dermatitis was made and corticosteroid and cephalosporin treatment was given. Further skin lesions on the head, the neck, the anterior limbs and the tail followed. Initial lesions appeared as papules which later ulcerated and formed scabs. The ulcerated areas were between 10 and 15 mm in diameter.

One month after the onset of the disease a skin biopsy was carried out. Based on the presumptive diagnosis of poxvirus infection, corticosteroid treatment was interrupted.

To confirm this diagnosis a second skin biopsy was performed for electron microscopical investigation and a

sterile skin scraping taken for virus isolation. They were carried out in the late stage of the disease, about fifty days after the cutaneous lesions had appeared. By that time the patient had only few scabby areas on the paws and the tail. A complete recovery occurred about seventy-five days after the onset of the disease, at that time the hair started to grow over the less damaged areas, while the more severely injured ones remained alopecic.

### Histopathology

The tissue sample was placed in 10% formaline, embedded in paraffin and the sections were stained with haematoxylin and eosin (HE) and with periodic acid Schiff (PAS) reaction.

### Electron microscopy (EM)

The tissue sample fixed with 2.5% glutaraldehyde in 0.1 M cacodylate buffer, pH 7.3 and postfixed with 1% osmium tetroxide in the same buffer, was embedded in epon/araldite; ultrathin sections were stained with uranyl acetate and lead citrate. Negative staining for EM examination of scabby material was performed using both the "drop method" and the method of direct pelleting of viral particles on grids. The first consists of the observation of a viral suspension obtained directly by the homogenisation of the scabs in a mortar with few drops of phosphate buffered saline, pH 7.2. Carbon coated grids were floated on a drop of viral suspension for 10 minutes. The second method was performed according to those previously reported (Lavazza et al., 1990). The negative staining was carried out by 2.5% sodium phosphotungstate, pH 6.8, for 1.5 minutes.

### Virus isolation

For virus isolation chorioallantoic membrane (CAM) of 12 day old chick embryos were inoculated with an extraction of scabs made in simple broth with antibiotics. Eggs were candled daily. Since no specific lesions were detected after six days of incubation at 37 °C., CAM were harvested and used for carrying out further passages.

## Results

### Histopathology

Sections stained by HE showed extensive areas of lysis and ulceration of the epidermis and ballooning degeneration of the stratus spinosum. Some cells of the stratus spinosum of the epidermis and a few cells of the hair follicles contained oval eosinophilic intracytoplasmic inclusion bodies (Fig.1), which did not stain with PAS reaction. A diffuse dermal inflammatory infiltrate of neutrophils, macrophages and mononuclear cells was also present.

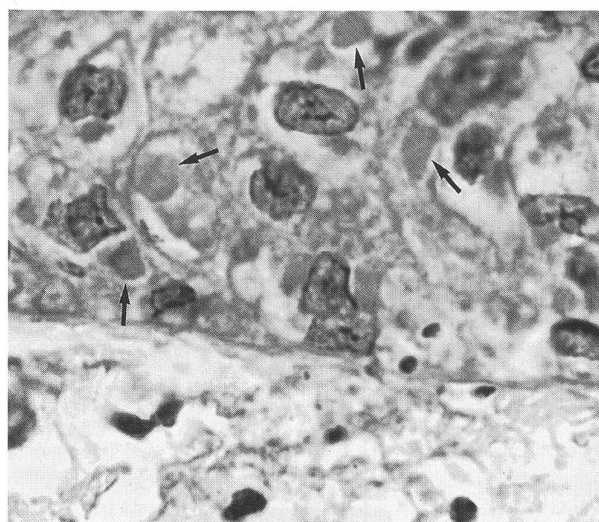


Figure 1: Histologic section of the skin. Some keratinocytes show cytoplasmic inclusions (arrows) suggestive of poxvirus infection. (HE 4000 X)

### Electron microscopy

The EM examination of the tissue sample revealed the presence of virus particles in the spinosum cells of the epidermis, morphologically similar to Orthopoxvirus. They appeared ovoid with a central thickening and a biconcave nucleoid. They also showed an outer membrane. Their dimensions varied according to the section of plane (Fig.2).

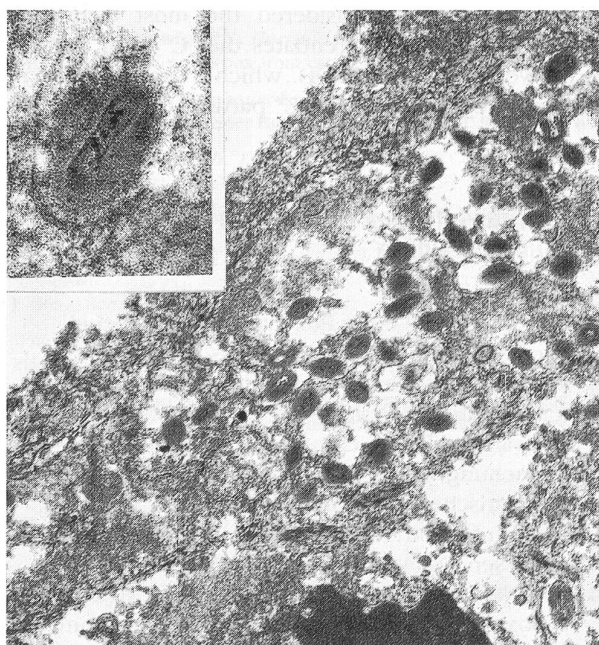


Figure 2: Skin biopsy. Electron micrograph of an infected keratinocyte, showing cytoplasmic poxvirus particles (20 000 X). Insert: at higher magnification a virus particle clearly showing a nucleoid (100 000 X)




Figure 3: Electron micrograph of a negatively stained viral particle from scabs.

The EM examination of both the scabs and the underlying exudate by negative stain revealed the presence of viral particles morphologically related to the genus orthopoxvirus. Their size was approximately  $320 \times 238$  nm (range  $320\text{--}350 \times 215\text{--}250$ ) and they exhibited the typical bricklike shape. Almost all the virions presented the morphological aspect known as "C" form (Fig. 3), and the ribbon structure of the viral surface was not detectable. This is considered the most distinctive characteristic that differentiates the "C" from the "M" form (Westwood et al., 1964), which is usually prevalent in fresh preparations. The "C" particle of our samples

may be also differentiated from "M" forms because they were slightly larger, showed an uniform electron density and had a thick capsule outlined by a ragged edge.

### Virus isolation

No specific lesions were observed in any infected CAM.

## Discussion

The presence of eosinophilic cytoplasmic A type inclusions in the epithelial cells of the skin lesions and the observation of particles morphologically related to the orthopoxvirus in both tissue and scab samples by EM, confirm the poxvirus infection in our case.

CAM virus isolation is believed to be one of the most sensitive tests for the diagnosis of poxvirus infection (Bennett et al., 1985). In our case we did not observe the typical haemorrhagic pocks induced by the virus infection of CAM. Bennett and co-workers (1985) in twenty-eight cases of naturally occurring feline poxvirus infection, isolated the virus in twenty-five cases. Of the three negative ones two were convalescent animals and the other an acute case. In our study the sample for virus isolation was taken in the late stage of the disease, when the patient had very few scabby areas. Therefore the hypothesis of an already well established immunological resistance can be postulated. Such a hypothesis may be confirmed by the EM detection of the prevalence of less infective "C" particles.

The disease in this case was limited to the skin, with a clinical appearance similar to the ones reported in the cat by different authors (Martland et al., 1983, 1985; Gaskell et al., 1983; Hoare and Bennett, 1985; Bennett et al., 1985). No symptoms of systemic infection were

### Poxvirus-Infektion einer Katze. Fallbeschreibung

Es wird ein Fall einer Poxvirus-Infektion bei einer Katze beschrieben. Das klinische Bild war ausschliesslich durch Läsionen der Haut charakterisiert, die im Verlauf von 10 Wochen verschwanden. Durch eine histopathologische Untersuchung wurde die Anwesenheit von zytoplasmatischen Einschlusskörperchen, die für eine virale Infektion der Epidermis typisch sind, nachgewiesen. Das ultrastrukturelle Bild gestattete den Nachweis von viralen Partikeln, die dem Orthopoxvirus angehören, sowohl in Gewebsschnitten der Haut als auch in Extrakten der Ulcera der Haut. Die letzteren jedoch haben zu keinen spezifischen Läsionen der Chorioallantois bei Hühnerembryonen geführt.

### Infection de poxvirus dans le chat. Description d'un cas

Il vien reporté un cas d'infection de Poxvirus dans un chat. Le cadre clinique etait caracterisé exclusivement par de lesions cutanées et la maladie s'est resolué dans l'espace de deux mois et demi. L'observation istopatologique nous a permis de remarquer la presence de corps inclus cytoplasmique tipique de l'infection virale à la charge de l'épiderme. L'anquête ultrastructurale a permis d'identifier particules virales reportable à Orthopoxvirus soit sur de sections du tissu cutané, soit dans l'extrait d'ulceres cutanées; mais ce dernier n'a pas provoqué lesions tipiques dans les membranes chorionallantoidiennes d'embryon de poulet.



detectable in spite of corticosteroid therapy. Steroid treatment is believed to be counterindicated by the majority of authors (Webster and Jefferies, 1984; Hoare et al., 1984; Naidoo et al., 1989) due to the risk of causing more severe and systemic illness. In our case the slight delay of the full recovery, generally evaluated between four and eight weeks (Martland et al., 1983; Zimmer et al., 1990) might be due to the corticosteroid administration. The case reported here is the first one described in Italy. The majority of the cases of cowpox virus infection in domestic cats have been recorded from the UK, but sporadic cases have been reported in Austria (Schoenbauer et al., 1982) and Germany (Zimmer et al., 1990). It is our opinion that the disease in Italy might be misdiagnosed. The clinical appearance is not diagnostic of the disease and the confirmation of poxvirus infection requires virus isolation or virus identification in the biopsy, that is rarely performed. Detection of seropositivity with specific antibodies also appears to be another reliable diagnostic method (Bennett et al., 1985; Naidoo et al., 1989). The observation that 13.5% of 104 healthy cat sera showed seropositivity for the pox virus antibodies (Zimmer et al., 1990) highlights the hypothesis that pox virus infection of the cat might be widespread and misdiagnosed and that the cat may also be a healthy carrier of this virus.

Although cowpox virus infection is not endemic in cattle or cat, and the reputed reservoir of the virus is thought to be an unknown small wild mammal, probably a rodent (Baxbay, 1977, 1984; Baxbay et al., 1979; Gaskell et al., 1983; Hoare et al., 1985), cat-to-cat transmission has been proven experimentally (Bennett et al., 1989) and reports of cat-to-man infections have become increasingly frequent (Baxbay et al., 1985; Willemse and Egberink, 1985; Pether et al., 1986; Hall and Stevens, 1987; Zimmer et al., 1990; Eis-Hubingher et al., 1990). These observation should be kept in mind by veterinary practitioners, who must consider the occurrence of poxvirus infection when diagnosing cat skin lesions, especially when they are therapy resistant.

## References

- Baxbay D. (1977): Is cowpox misnamed? A review of ten human cases. *Br. Med. J.* 1, 1379-1381.
- Baxbay D., Ashton D.G., Jones D., Thomsett L.R., Denbam E.M. (1979): Cowpox virus infection in unusual hosts. *Vet. Rec.* 104, 175.
- Baxbay D., Ashton D.G., Jones D.M., Thomsett L.R. (1982): An outbreak of cowpox in captive cheetahs: virological and epidemiological studies. *J. Hyg. Camb.* 89, 365-372.
- Baxbay D. (1984): Cowpox infection of cats. *Vet. Rec.* 115, 91.
- Baxbay D., Bennett M., Gaskell R.M. (1985): Medical implication of feline cowpox. *Lancet*, ii, 45.
- Bennett M., Baxbay D., Gaskell R.M., Gaskell C.J., Kelly D.F. (1985): The laboratory diagnosis of Orthopoxvirus infection in the domestic cat. *J. Small Anim. Pract.* 26, 653-661.
- Bennett M., Gaskell C.J., Gaskell R.M., Baxbay D., Gruffydd-Jones T.J. (1986): Poxvirus infection in the domestic cat: some clinical and epidemiological observations. *Vet. Rec.* 118, 387-390.
- Bennett M., Gaskell R.M., Gaskell C.J., Baxbay D., Kelly D.F. (1989): Studies on poxvirus infection in cats. *Arc. Virol.* 104, 19-33.
- Eis-Hubingher A.M., Gerritzen A., Schneeweis K.E., Pfeiff B., Pullman H., Mayr A., Czerny C.P. (1990): Fatal cowpoxlike infection transmitted by cat. *Lancet*, ii, 880.
- Gaskell R.M., Gaskell C.J., Evans R.J., Dennis P.E., Bennett M., Udall N.D., Voyle C., Hill T.J. (1983): Natural and experimental pox virus infection in the domestic cat. *Vet. Rec.* 112, 164-170.
- Hall C.J., Stevens J.D. (1987): Ocular cowpox. *Lancet*, i, 111.
- Hoare C.M., Gruffydd-Jones T.J., Bennett M., Gaskell R.M., Baxbay D. (1984): Cowpox in cats. *Vet. Rec.* 114, 22.
- Hoare C.M., Bennett M. (1985): Cowpox in the cat. *Vet. Ann. Grensell C.S.G., Hill F.W.G., Raw M.E., Edrs. Scientifica Inc. Bristol*, pp 348-351.
- Lavazza A., Pascucci S., Gelmetti D. (1990): Rodshaped virus-like particles in intestinal contents of three avian species. *Vet. Rec.* 126, 581.
- Martland M.F., Fowler S., Poulton G.J., Baxbay D. (1983): Pox virus infection in domestic cat. *Vet. Rec.* 112, 171-172.
- Martland M.F., Poulton G.J., Done R.A. (1985): Three cases of cowpox infection of domestic cats. *Vet. Rec.* 117, 231-233.
- Naidoo J., Gaskell J., Gaskell R.M., Baxbay D., Bennett M. (1989): Cowpox in cats. *Vet. Rec.* 125, 465.
- Pether J.V.S., Trevains P.H., Harrison S.R.B., Baxbay D., Bennett M., Gibb A.P.R. (1986): Cowpox from cat to man. *Lancet*, i, 38-39.
- Schoenbauer M., Schoenbauer-Laengle A., Kolbl S. (1982): Pockeninfektionen bei einer Hauskatze. *Zbl. Vet. Med. B.* 29, 434-440.
- Thomsett L.R., Baxbay D., Denbam E.M.H. (1978): Cowpox in the domestic cats. *Vet. Rec.* 108, 567.
- Webster J., Jefferes J.R. (1984): Cowpox in cats. *Vet. Rec.* 114, 151.
- Westwood J.C.N., Harris W.J., Zwartow H.T., Titmuss D.H.J., Appleyard G. (1964): Studies on the structures of vaccinia virus. *J. Gen. Microbiol.* 34, 67-68.
- Willemse A., Egberink H.F. (1985): Transmission of cowpox virus infections from domestic cats to man. *Lancet*, i, 1515.
- Zimmer K., Bogantes J.C., Herbst W., Rother W. (1990): Poxvirus infection in a cat and its owner. *Schweiz. Arch. Tierheilk.* 132, 484.

Address of the authors: Prof. Maria G. Canese, Dipartimento di Patologia Animale, Via Nizza 52, I-10126 Torino, Italy

Manuskripteingang: 25. März 1996