

Detection of human carcinoma by immunoscintigraphy using monoclonal anti-CEA antibodies

Autor(en): **Forni, Michel / Ritschard, Jürg / Buchegger, Franz**

Objektyp: **Article**

Zeitschrift: **Jahrbuch der Schweizerischen Naturforschenden Gesellschaft. Wissenschaftlicher und administrativer Teil = Annuaire de la Société Helvétique des Sciences Naturelles. Partie scientifique et administrative**

Band (Jahr): **162 (1982)**

PDF erstellt am: **22.07.2024**

Persistenter Link: <https://doi.org/10.5169/seals-90900>

Nutzungsbedingungen

Die ETH-Bibliothek ist Anbieterin der digitalisierten Zeitschriften. Sie besitzt keine Urheberrechte an den Inhalten der Zeitschriften. Die Rechte liegen in der Regel bei den Herausgebern.

Die auf der Plattform e-periodica veröffentlichten Dokumente stehen für nicht-kommerzielle Zwecke in Lehre und Forschung sowie für die private Nutzung frei zur Verfügung. Einzelne Dateien oder Ausdrucke aus diesem Angebot können zusammen mit diesen Nutzungsbedingungen und den korrekten Herkunftsbezeichnungen weitergegeben werden.

Das Veröffentlichen von Bildern in Print- und Online-Publikationen ist nur mit vorheriger Genehmigung der Rechteinhaber erlaubt. Die systematische Speicherung von Teilen des elektronischen Angebots auf anderen Servern bedarf ebenfalls des schriftlichen Einverständnisses der Rechteinhaber.

Haftungsausschluss

Alle Angaben erfolgen ohne Gewähr für Vollständigkeit oder Richtigkeit. Es wird keine Haftung übernommen für Schäden durch die Verwendung von Informationen aus diesem Online-Angebot oder durch das Fehlen von Informationen. Dies gilt auch für Inhalte Dritter, die über dieses Angebot zugänglich sind.

Detection of human carcinoma by immunoscintigraphy using monoclonal anti-CEA antibodies

Michel Forni, Jurg Ritschard, Franz Buchegger, Charles Haskell, Stephan Carrel and Jean-Pierre Mach

Early experimental results

Research on tumour localization of radio-labeled antibodies was initiated almost 30 years ago by Pressman (1) and Bale (2), who showed that labeled antibodies against Wagner osteosarcoma or Walker carcinoma cells were concentrated *in vivo* by these tumors.

In 1974, we introduced into this field the model of nude mice bearing grafts of human colon carcinoma and the use of affinity pu-

rified antibodies against carcinoembryonic antigen (CEA) (3). We showed that purified ^{131}I -labeled goat anti-CEA antibodies could reach up to a 9 times higher concentration in the tumor than in the liver, while the concentration of control normal IgG in the tumor was never higher than 2.3 times that in the liver. We observed, however, great variations in the degree of specific tumor localisation by the same preparation of labeled antibodies, when colon carcinoma grafts de-

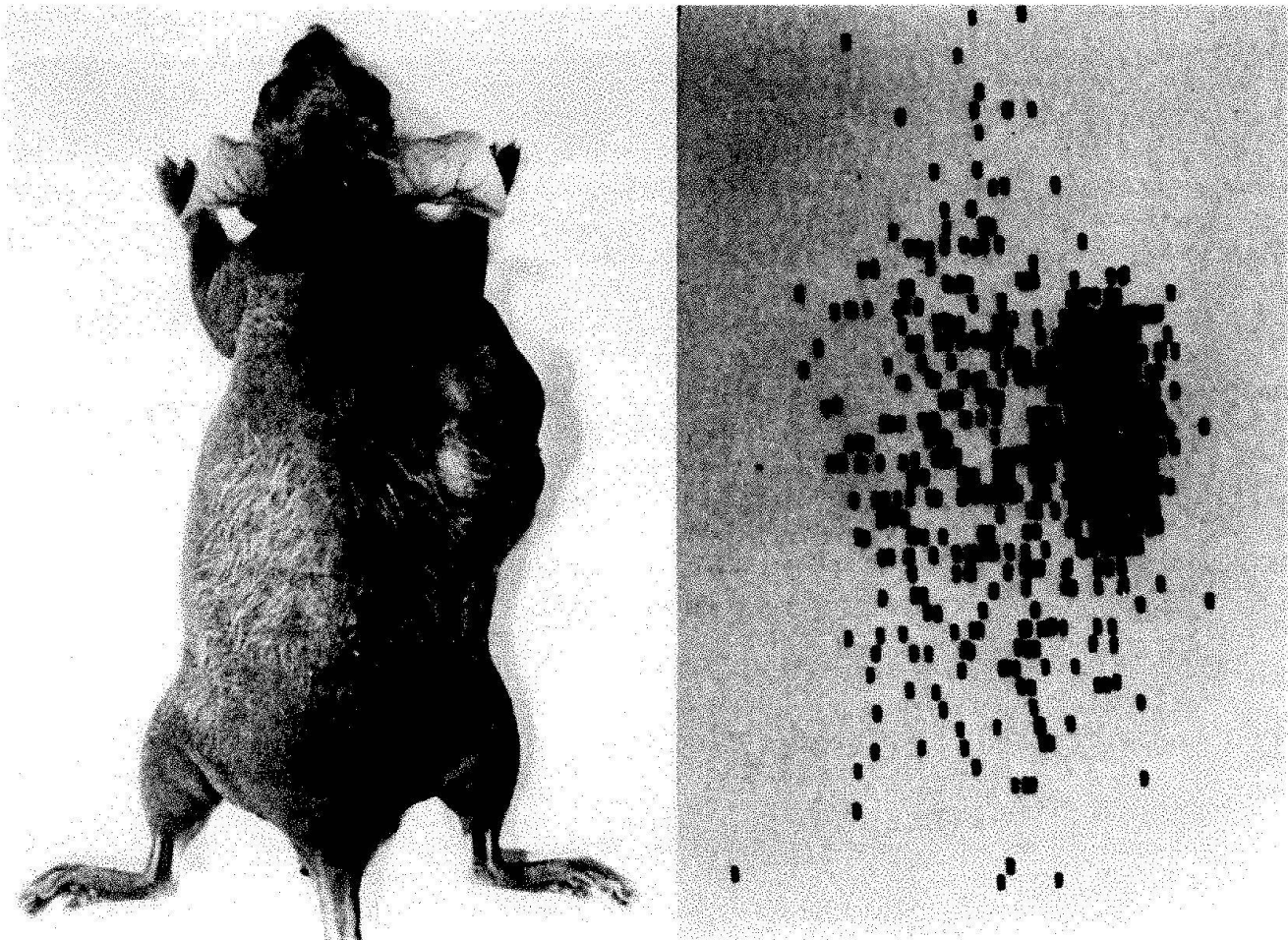


Fig. 1. Scanning of a nude mouse which received an injection of ^{131}I -labeled anti-CEA antibodies. A. Nude mouse bearing a xenograft of human colon carcinoma shown in the scanning position. B. The total body scan from the same mouse obtained 3 days after injection of 2 μg of ^{131}I -labeled anti-CEA antibodies (dose of radioactivity injected = 16 μCi). (Reproduced with the permission of *Nature*) (3).

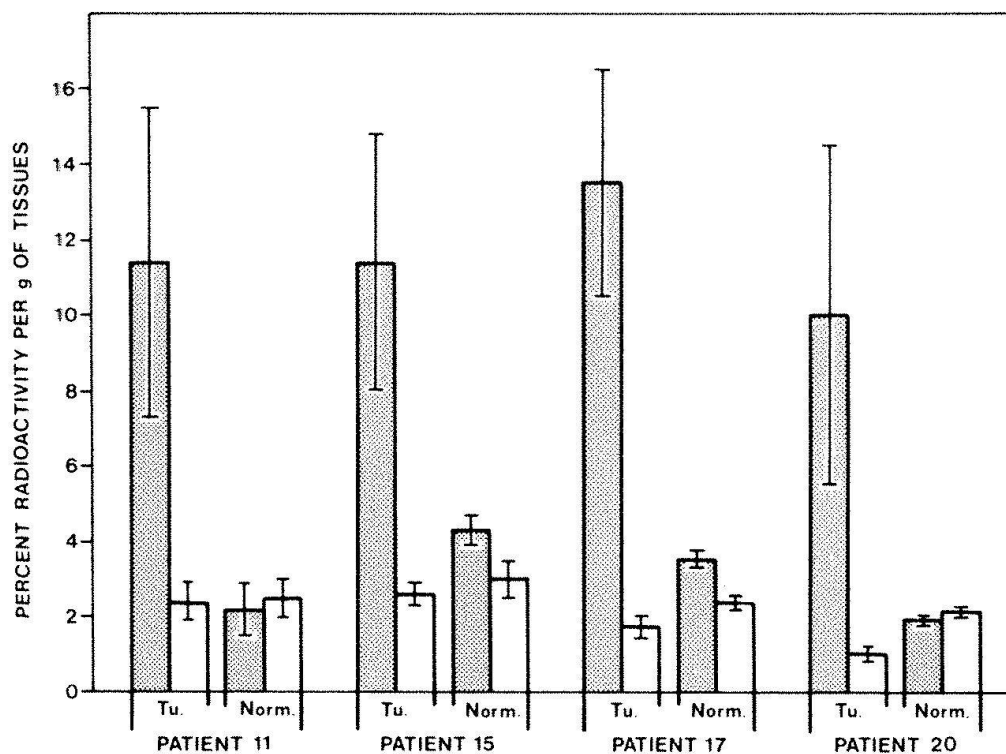


Fig. 2. Specific tumor uptake of anti-CEA antibodies in patients with colon carcinoma. The shaded areas show the relative concentration of ^{131}I -labeled control normal goat IgG, in both tumor (Tu.) and normal mucosa (Norm.) from four patients who received simultaneous injections of both labeled proteins 3-8 days before surgery. The vertical solid lines show the standard deviation of the results obtained in individual tissue fragments. The radioactivity of each isotope present in each fragment was measured in a dual channel gamma counter. (Reproduced with the permission of *N. Engl. J. Med.*) (8).

rived from different donors were tested. This is probably due to the fact that human tumors keep their initial histologic properties and degree of differentiation after transplantation into nude mice and these two factors appear to affect the ease with which circulating antibodies gain access to the CEA present in tumors. The detection of ^{131}I -labeled antibodies in tumors by external scanning also gave variable results. With colon carcinoma grafts from certain donors we obtained scans with good tumor localisation, such as the one presented in figure 1, whereas with colon carcinoma grafts from other donors the antibody uptake was not sufficient to give satisfactory scanning images. In this context we think that results in the nude mouse model are a good reflection of the clinical reality observed in patients.

Independently, Goldenberg *et al.* (4) showed specific tumor localisation and detection by external scanning with ^{131}I -labeled IgG fractions of anti-CEA serum, using two human carcinomas which had been serially transplanted into hamsters for several years. Using the same experimental model Hoffer *et al.* (5) also demonstrated tumor localisation with radiolabeled IgG anti-CEA by external scanning.

Clinical results with polyclonal anti-CEA antibodies

The first detection of carcinoma in patients obtained by external scanning following injection of purified ^{131}I -labeled anti-CEA antibodies was reported by Goldenberg *et al.* (6,7). They claimed that almost all the CEA producing tumors could be detected by this method and that there was no false positive results. However, our experience, using highly purified goat anti-CEA antibodies and the same blood pool subtraction technology as Goldenberg was that only 42% of CEA producing tumors (22 out of 53 tested) could be detected by this method (8-9). Furthermore, we found that in several patients the labeled anti-CEA antibodies localized non-specifically in the reticuloendothelium. Despite the use of the subtraction technology, these non-specific uptakes were difficult to differentiate from the specific uptakes corresponding to the tumors. This discrepancy of results is unlikely to be due to a difference in the quality of the anti-CEA used since we showed by direct measurement of the radioactivity in tumors resected after injection, that our antibody was capable of excellent tumor localization (8) (fig. 2). Furthermore, in a few patients scheduled for

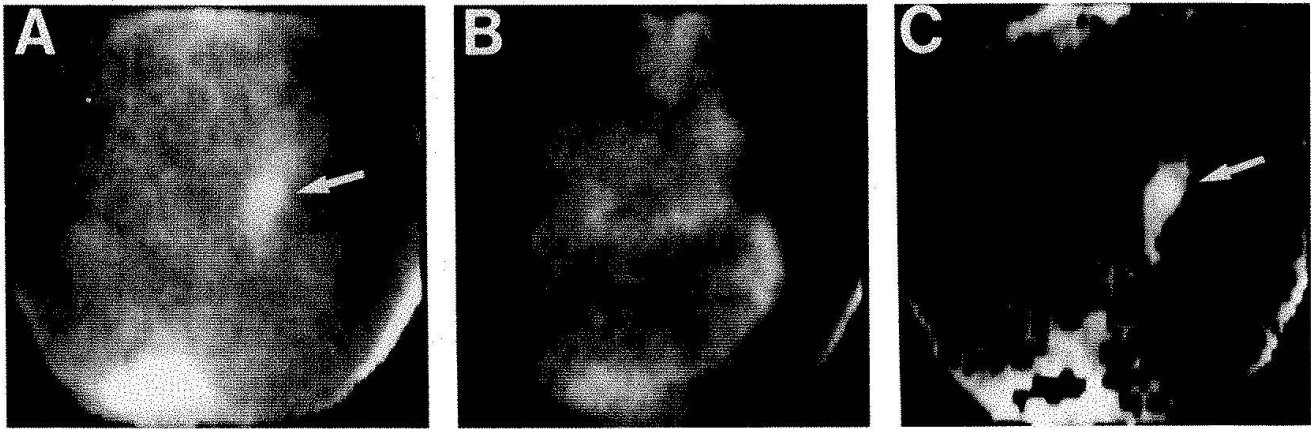


Fig. 3. Localization of carcinoma by external photoscanning after injection of radiolabeled $F(ab')_2$ fragments of monoclonal antibodies against CEA. Anterior left lateral photoscans of the whole abdomen and pelvis of a patient who received an injection of ^{131}I -labeled $F(ab')_2$ fragments of Mab 35, 48 hrs before scanning. The patient had a metastasis of a carcinoma of the ovary, located deep in the abdomen below the umbilicus. Panel A shows the total ^{131}I radioactivity, panel B the ^{99}Tc radioactivity due to injection of ^{99}Tc -labeled HSA and free $^{99}\text{TcC}_4$, 15 min before scanning. Panel C shows the remaining ^{131}I radioactivity after subtraction of ^{99}Tc radioactivity. In panel A and C the arrow indicate the radioactive spot corresponding to the tumor.

tumor resection, we injected simultaneously 1 mg of goat anti-CEA antibodies labeled with 1 mCi of ^{131}I and 1 mg of control normal goat IgG labeled with 0.2 mCi of ^{125}I . By this paired labeled method adapted to the patient situation, we could demonstrate that the antibody uptake was 4 times higher than that of control normal IgG (8) (fig. 2).

These results were very encouraging in terms of specificity of tumor localization. However, the direct measurement of radioactivity in tumors also showed that only 0.05-0.2% of the injected radioactivity (0.5-2 μCi out of 1000 μCi) were recovered in the resected tumors 3-8 days after injection (8). This information is essential if one is considering the use of ^{131}I labeled antibody for therapy (10).

Monoclonal anti-CEA antibody used in photoscanning

The obvious advantage of monoclonal antibodies (Mabs) are their homogeneity and their specificity for the immunizing antigen. Another advantage of Mabs is that they each react with a single antigenic determinant and thus should not be able to form large immune complexes with the antigen (provided that the antigenic determinant is not repetitive).

The first Mab anti-CEA used for immunoscintigraphy in patients was Mab 23 (11). Its

production and characteristics have been described (12). Mab 23 was given intravenously to 26 patients with large bowel carcinomas and 2 patients with pancreatic carcinomas. Each patient received 0.3 mg of purified Mab labeled with 1-1.5 mCi of ^{131}I . The patient's premedication included lugol 5 percent iodine solution, promethazine and prednisolone, as previously described (8,9). The patients had no personal history of allergy. They were also tested with an intracutaneous injection of normal mouse IgG and found to have no hypersensitivity against this protein. None of the patients showed any sign of discomfort during or after the injection of labeled mouse antibodies. The patients were studied by external photoscanning 24, 36, 48 and 72 h after injection. An Elscint large-field camera with an LFC9 high-energy parallel-hole collimator was used. In 14 of the 28 patients (50%) a radioactive spot corresponding to the tumor was detected 36-48 h after injection. In 6 patients the scans were doubtful and in the remaining 8 patients they were entirely negative (11).

In order to improve these results we produced a series of 26 new hybrids secreting anti-CEA antibodies. Three of them were selected by criteria of high affinity for CEA of the antibody produced (13). The new selected Mabs designated 202, 35 and 192 were purified and tested for the detection of human carcinoma grafted in nude mice both in the form of intact Mab and in the form of

F(ab')₂ and Fab fragments. The results showed that the fragment of Mabs were markedly superior to the intact Mab for the detection of human carcinoma in the nude mouse model (14).

One of the positive scanning studies obtained recently with the F(ab')₂ fragment of Mab 35 is illustrated in figure 3. The patient was an 87 years old female with a retroperitoneal metastasis of a carcinoma of the ovary. The tumor was palpable below the umbilicus and found by CAT SCAN to consist of a solid masse of 13x9 cm diameter. Figure 3 shows the anterior-lateral photoscans (camera to the left of the patient) of the abdomen and pelvis, taken 48 hrs after injection of 0.3 mg of Mab 35 F(ab')₂ labeled with 1.5 mCi of ¹³¹I (55.5 MBq). Panel A shows the total ¹³¹I radioactivity; one sees a diffuse radioactive spot in the center right of the scan (arrow) corresponding to the tumor. Abundant radioactivity is also present in the lower left part of the scan corresponding to the urinary bladder which was not properly emptied. Panel B shows the ^{99m}Tc radioactivity due to the injection, 15 min before scanning, of 500 µCi (18.5 MBq) of ^{99m}Tc labeled human serum albumin and 500 µCi of free ^{99m}TcO₄⁻. There are diffuse spots of radioactivity in the stomach, spleen and bladder as well as in the left side of the abdomen but these spots do not correspond to the localization of the tumor. Panel C shows the ¹³¹I radioactivity after computerized subtraction of the ^{99m}Tc radioactivity. Here, the major central radioactive uptake corresponding to the tumor is well contrasted. The urinary bladder remained positive despite the subtraction.

Tumor detection by tomoscintigraphy

Another way to improve tumor detection by immunoscintigraphy is the use of tomoscintigraphy. As we have seen, static photoscanning is limited in part by the presence of radiolabeled antibodies or free ¹³¹I released from them, in the circulation, the reticuloendothelial system, the stomach, intestine and urinary bladder. Increased radioactivity in these compartments may give false positive results. Specific tumor sites may be masked by non-specific radioactivity. These problems cannot be entirely re-

solved by the presently available subtraction methods using ^{99m}Tc labeled HSA and free ^{99m}TcO₄⁻. Axial transverse tomoscintigraphy is a method initially developed by Kuhl and Edwards in 1973 (15) with the potential to resolve some of these problems. This method, also called single photon *emission* computerized tomography (SPECT), corresponds to the application of the tomographic technique used in *transmission* computerized axial tomography (CAT) to scintigraphic data. Mathematical techniques similar to those used in positron and X-ray tomographies allows the reconstruction of transverse sections as well as frontal, saggital or oblique sections of patients. In collaboration with Ch. Berche and J.-D. Lumbroso from the Institut Gustave Roussy in Villejuif, we have recently shown that tomoscintigraphy can improve the sensivity and specificity of tumor detection by radiolabeled anti-CEA Mabs (16). With this methods 15 out of 16 carcinoma tumor sites studied (including 10 colorectal carcinomas, 1 stomach, 1 pancreas and 4 medullary thyroid carcinomas) were detectable. These results are encouraging in term of sensitivity. However, it should be noted that numerous non-specific radioactive spots, sometimes as intense as the tumors were observed. Thus, the problem of non-specific accumulation of antibodies remains, but the three dimensions localization of radioactive spots by tomoscintigraphy, helped to discriminate specific tumor uptakes from the non-specific ones (16).

Antibody and control radioactivity in resected tumors

A few patients scheduled for tumor resection were injected simultaneously with 1 mCi of ¹³¹I-labeled Mabs and 0.2 nCi of ¹²⁵I-labeled purified normal mouse IgG. The radioactivity of both isotopes was measured in the resected tumors and adjacent normal tissues and the specificity of tumor locatization studied by differential radioactive analysis, as shown in table 1. One sees that the factors of radioactivity uptake (indicated in parentheses) range from 2.7 to 7.4 for Mab 23 when one compares tumor with normal mucosa. They are even higher when one com-

Table 1. Specificity of tumor localisation of monoclonal anti-CEA antibodies as compared to normal IgG*

Case No. Tumour site	Tumour weight	Material injected	Tot.nCi Tumour	nCi/g		Tumour**		nCi/g		Tumour**	
				Tumour	N.mucosa	N.mucosa	N.mucosa	N.serosa	N.serosa	nCi/ml serum	Tumour** serum
63) Tr.colon op.d.6; CEA = 1.2	15 g	Mab 23 ¹³¹ I N.-IgG ¹²⁵ I	425 45	28.3	10.3	(2.7)**	3.5***	6.6	(4.3)	30.3	(0.9) 5.4
				3.0	3.8	(0.8)		3.3	(0.9)	17.5	(0.17) 5.4
67) Left colon op.d.8; CEA = 1.1	16 g	Mab 23 ¹³¹ I N.-IgG ¹²⁵ I	196 50	12.3	4.6	(2.7)**	2.2***	2.5	(4.9)	17.7	(0.7) 3.3
				3.1	2.5	(1.2)		1.9	(1.6)	14.8	(0.2) 3.3
73) Left colon op.d.4; CEA = 2.7	28 g	Mab 23 ¹³¹ I N.-IgG ¹²⁵ I	1,052 77	38.4	11.3	(3.4)**	2.4***	7.8	(4.9)	45.4	(0.8) 3.8
				2.8	2.0	(1.4)		2.1	(1.3)	13.3	(0.21) 3.8
81) Sigmoid op.d.5; CEA = 150	50 g	F(ab') ₂ 23 ¹³¹ I N.-IgG ¹²⁵ I	897 184	17.9	2.4	(7.4)**	4.6***	1.8	(10.1)	7	(2.6) 8.4
				3.7	2.3	(1.6)		2.4	(1.5)	12	(0.31) 8.4

* Abbreviations: Tot.nCi Tumour = Total radioactivity in tumour in nanoCuries; nCi/g = concentration in nCi per gram; N.mucosa = dissected normal mucosa; N.serosa = dissected external bowel wall; op.d.6 = patient operated 6 days after injection. CEA = 1.2 means: serum CEA level of 1.2 ng per ml (28).

** Factors of radioactivity uptake in tumor (indicated in parantheses) are obtained by dividing the concentration of radioactivity in tumor by the concentration of radioactivity either in N.mucosa, N.serosa or serum.

*** Specificity indices (underlined figures) are calculated by dividing the factor of radioactivity uptake obtained for ¹³¹I antibody by the same factor obtained for ¹²⁵I normal IgG.

compares the tumor with the bowel wall stripped from the mucosa (normal serosa). In contrast, the same factors calculated for the control normal IgG ranged between 0.8-1.6. If one divides the factors of uptake calculated for antibodies by those calculated for normal IgG one obtains the indices of specific tumor localisation of antibodies. The average of these indices for the 4 patients analysed here is 4.3 (range 2.2-8.4). The 4 cases presented here all had positive scans.

Discussion

It is evident from this brief review of our recent results that the method of immunoscintigraphy for the detection of solid tumors can be improved by the use of Mabs selected for higher specificity and affinity for CEA. Other possibilities of improvement of immunoscintigraphy includes the use of Mabs against newly discovered tumor markers and the use of other isotopes for the radio-labeling of Mabs. In collaboration with the group of H. Koprowski, we have recently shown that a Mab (17-1A) directed against a new colorectal carcinoma marker can be used for the detection by scintigraphy of these tumors in patients (17). Other groups have used a Mab raised against human osteosarcoma to detect colorectal carcinomas (18) or Mabs against milk fat globule antigens to detect human carcinoma of various origin (19). It is clear that all these results need to be confirmed on well controlled clinical studies before they can be recommended for large scale use.

Concerning new isotopes, chelates, such as diethylenetriamine pentaacetic acid (DTPA) have been used to label antibodies with ¹¹¹In-dium (20, 21) which in terms of specific energy and physical half live is particularly suitable for immunoscintigraphy. An advantage of DTPA is that it can also be used to label antibodies with different alpha-emitting isotopes which represent the best potential agents for the destruction of tumor cells (21). Critical experimental investigations are, however, necessary, before such type of radioimmunotherapy can be considered for the treatment of cancer patients.

References

- Pressman, D. and Korngold, L. The in vivo localization of anti-Wagner osteogenic sarcoma antibodies. *Cancer* 6: 619-623, 1953.
- Bale, W.F., Spar, I.L., Goodland, R.L. and Wolfe, D.E. In vivo and in vitro studies of labeled antibodies against rat kidney and Walker carcinoma. *Proc. Soc. Exp. Biol. Med.* 89: 564-568, 1955.
- Mach, J.-P., Carrel, S., Merenda, C., Sordat, B. and Cerottini, J.-C. In vivo localisation of radiolabeled antibodies to carcinoembryonic antigen in human colon carcinoma grafted into nude mice. *Nature* 248: 704-706, 1974.
- Goldenberg, D.M., Preston, D.F., Primus, F.J. and Hansen, H.J. Photoscan localization of GW-39 tumors in hamsters using radiolabeled anti-carcinoembryonic antigen immunoglobulin G. *Cancer Res.* 34: 1-9, 1974.
- Hoffer, P.B., Lathrop, K., Bekerman, G., Fang, V.S. and Refetoff, S. Use of ^{131}I -CEA antibody as a tumor scanning agent. *J. Nucl. Med.* 15: 323-327, 1974.
- Goldenberg, D.M., DeLand, F., Enishin, K., Bennett, S., Primus, F.J., van Nagell, J.R., Estes, N., DeSimone, P. and Rayburn, P. Use of radiolabeled antibodies to carcinoembryonic antigen for the detection and localization of diverse cancers by external photoscanning. *N. Engl. J. Med.* 298: 1384-1388, 1978.
- Goldenberg, D.M., Kim, E.D., DeLand, F.H., Bennett, S. and Primus, F.J. Radioimmunodetection of cancer with radioactive antibodies to carcinoembryonic antigen. *Cancer Res.* 40: 2984-2992, 1980.
- Mach, J.-P., Carrel, S., Forni, M., Ritschard, J., Donath, A. and Alberto, P. Tumor localization of radiolabeled antibodies against carcinoembryonic antigen in patients with carcinoma. *N. Engl. J. Med.* 303: 5-10, 1980.
- Mach, J.-P., Forni, M., Ritschard, J., Buchegger, F., Carrel, S., Widgren, S., Donath, A. and Alberto, P. Use and limitations of radiolabeled anti-CEA antibodies and their fragments for photoscanning detection of human colorectal carcinomas. *Oncodevelop. Biol. Med.* 1: 49-69, 1980.
- Order, S.E., Klein, J.L., Ettinger, D., Alderson, P., Siegleman, S. and Leichner, P. Use of isotopic immunoglobulin in therapy. *Cancer Res.* 40, 3002-3007, 1980.
- Mach, J.-P., Buchegger, F., Forni, M., Ritschard, J., Berche, C., Lumbroso, J.D., Schreyer, M., Girardet, Ch., Accolla, R.S. and Carrel, S. Use of radiolabelled monoclonal anti-CEA antibodies for the detection of human carcinomas by external photoscanning and tomoscintigraphy. *Immunology Today* 2: 239-249, 1981.
- Accolla, R.S., Carell, S. and Mach, J.-P. Monoclonal antibodies specific for carcinoembryonic antigen and produced by two hybrid cell lines. *Proc. Natl. Acad. Sci. (USA)* 77: 563-566, 1980.
- Haskell, C.M., Buchegger, F., Schreyer, M., Carrel, S. and Mach J.-P. In vitro screening of new monoclonal anti-CEA antibodies for radioimaging of human colorectal carcinomas. In R.E. Langman, I.S. Trowbridge and R. Dulbecco (Eds). *Monoclonal antibodies and Cancer* Academic Press New-York (in press).
- Buchegger, F., Haskell, C.M., Schreyer, M., Scazziga, B.R., Randin, S., Carrel, S. and Mach J.-P. Radiolabeled fragments of monoclonal anti-CEA antibodies for localization of human colon carcinoma grafted into nude mice, submitted for publication.
- Kuhl, D.E. and Edwards, R.D. Image separation radioisotope scanning. *Radiology* 80: 653-662, 1963.
- Berche, C., Mach, J.-P., Lumbroso, J.-D., Langlais, C., Aubry, F., Buchegger, F., Carrel, S., Rougier, P., Parmentier, C. and Tubiana, M. Tomoscintigraphy for detecting gastrointestinal and medullary thyroid cancers: First clinical results using radiolabelled monoclonal antibodies against carcinoembryonic antigen. *Brit. Med. J.* 285: 1447-1451, 1982.
- Mach, J.-P., Chatal, J.-F., Lumbroso, J.-D., Buchegger, F., Forni, M., Ritschard, J., Berche, C., Douillard, J.-Y., Carrel, S., Herlyn, M., Stepkowski, Z. and Koprowski, H. Submitted for publication.
- Farrands, P.A., Pimm, M.V., Embleton, M.J., Perkins, A.C., Hardy, J.D., Balwin, R.W., and Hardcastle, J.D. Radioimmunodetection of human colorectal cancers by an anti-tumor monoclonal antibody. *Lancet*, II: 397-400, 1982.
- Epenetos, A.-A., Mather S., Granowska, M., Nimmon, C.C., Hawkins, L.R., Britton, K.E., Shepherd, J., Taylor-Papadimitriou, J., Durbin, H., Malpas, J.S. and Bodmer, W.F. Targeting of iodine-123-labelled tumour associated monoclonal antibodies to ovarian, breast and gastrointestinal tumours. *Lancet* II: 999-1005, 1982.
- Khaw, B., Fallon, J.T., Strauss, H.W. and Haber, E. Myocardial infarct imaging of antibodies to canine cardiac myosin with Indium-111-diethylenetriamine pentaacetic acid. *Science* 209: 295-297, 1980.
- Scheinberg, D.A., Strand, M. and Gansow, O.A. Tumor imaging with radioactive metal chelates conjugated to monoclonal antibodies. *Science* 215: 1511-1513, 1982.

Address of the authors

Department of Medicine and
Division of Nuclear Medicine
University Hospital
CH-1211 Geneva (Switzerland)
and
Ludwig Institute for Cancer Research
Lausanne Branch
and the Department of Biochemistry
University of Lausanne
CH-1066 Epalinges (Switzerland)